

VETERINARY SURGEONS


Independence • Integrity • Innovation



www.stdavids-poultryteam.co.uk

Acute liver failure in free range laying hens

DANA SIMPSON DVM PGCERTVPS CERTAVP (POULTRY) MRCVS




- Recently converted commercial egg laying hen site from broiler breeders.
- 3 houses on site, 2 aviaries and 1 flat deck. 23,500 birds placed
- Communal range between the houses (not ideal)
- **Issues investigated earlier on in the flock due to uniformity problems resulting in suboptimal production**
 - Feeder track times adjusted
 - ABC Support® inclusion in the feed
 - Weekly weight monitoring advised



Production parameters history

- Visited at 19 weeks:
 - Birds transitioned well to the laying house
 - feed intake 96gr / hen / day on average.
 - Mortality 1-2 to date in each house
- Revisited at 28 weeks
 - Production dropped to 90.1% (average across the site)
 - Production recorded at 25 weeks was 94.5% across the site
 - Mortality increased in H2 to 3-4 a day (24 total in week 27)
 - Eggs not collected separately
 - Ranges not entirely separated
 - Record keeping could be better



Postmortem examination results from selected culled hens

H1(5)

- Weights 1840-1890gr with smaller than expected fat pads
- In lay with 5-6 follicles , pale livers (not enlarged)

H2 (5)

- Weights 1820 – 2070gr
- Large birds had large fat pads
- In lay with 5-6 follicles

H3 (5)


- Weights 1755 – 2010 gr
- Small fat pads in all, pale livers (not enlarged)
- In lay 5-7 follicles

No evidence of bacterial infection or internal parasites overall



Advice given at the visit

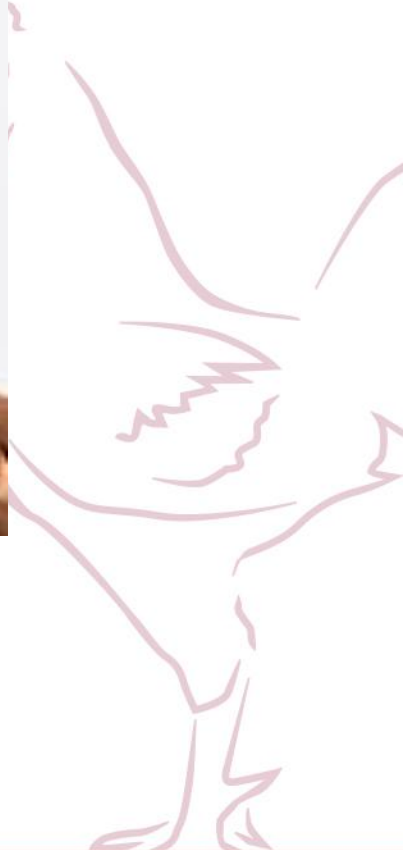
- The birds appear to be utilizing their reserves to sustain production. Advice was given to increase the running time of the tracks during the day feeds and review feeding activity and track depth between feeds.
- ABC support inclusion in the feed to help improve nutrient uptake and support intestinal gut health was advised for 4 weeks prior to being reviewed.
- Concern was raised regarding the uniformity of the flocks. Weighing of the birds weekly was advised to monitor progress and uniformity over the coming 4-6 weeks.



Follow up from the farmer

- Mortality has dropped to 1 a day in all houses
- Production increased to 92% average across the site
- Tracks are run for longer and feed appears to be consumed well
- The farmer reported an improvement in weight and uniformity however no weights were provided.





Things remained steady until...

At 52 weeks

- Capillaria worm eggs were detected at a routine sample check
- In-water wormer administered for 5 days (2mg/kg)
- Average bird weight and uniformity provided for the houses:

H1 2.00 kg average, 90% uniform


H2 1.96 kg average, 82.6% uniform

H3 1.97 kg average, 82 % uniform



Then...

- **An increase in mortality reported on day 3 of medication in H1**
- **PM carried out where swollen and congested livers , haemorrhagic abdominal fluid and pale carcasses were observed.**
- Swabs were collected for bacteriology (no growth yielded in 24 or 48 hours)
- Administration of the wormer was reviewed and appeared to be accurate.
- A visit suggested following a 48-hour period to review mortality and progress of disease
- The birds were not ranging due to being on medication
- Mortality had increased in all houses by the following day to 22 in H1, 16 in H2 and 16 in H3



Differential diagnosis

- Fatty liver Haemorrhagic syndrome

Livers enlarged	Livers dark and pulpy rather than pale and unyielding
Haemorrhages and ascites observed	Some light birds with small fat pads also affected

- Toxicosis (acute mycotoxicosis (Aflatoxin), rat poison)

Livers dark and congested	Raw material tested for Aflatoxins
Haemorrhagic fluid present in abdomen	No access to the range in the weeks prior to onset

- Avian influenza

It is the season...	Tested negative for AI exclusion
Sudden increase in mortality and lethargic hens	Mortality rates didn't increase rapidly in 48 hours


The farmer reported an improvement 24 hours after the worm treatment had finished.

A video of the birds was assessed and a visit was arranged



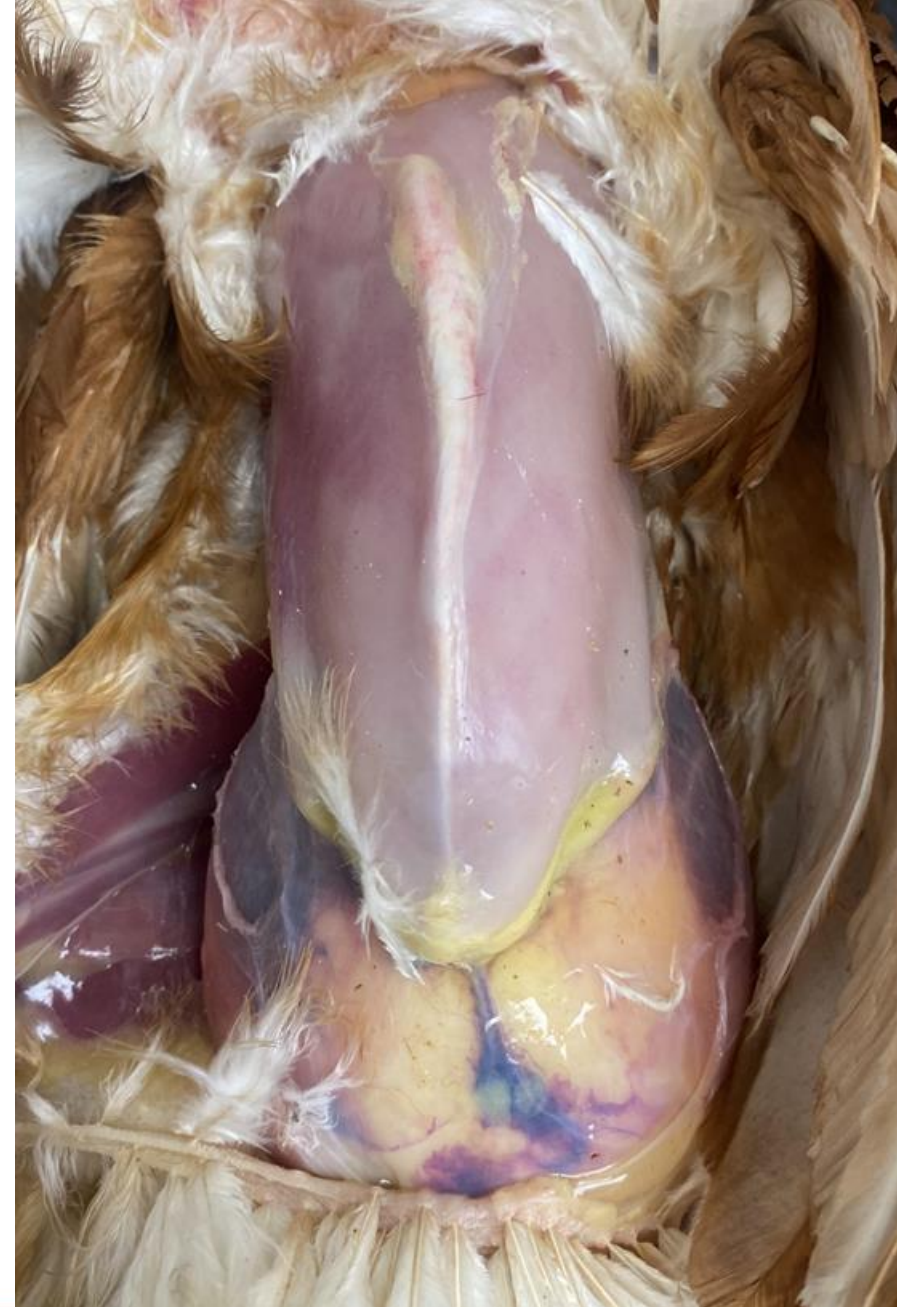Visit summary at 52 weeks

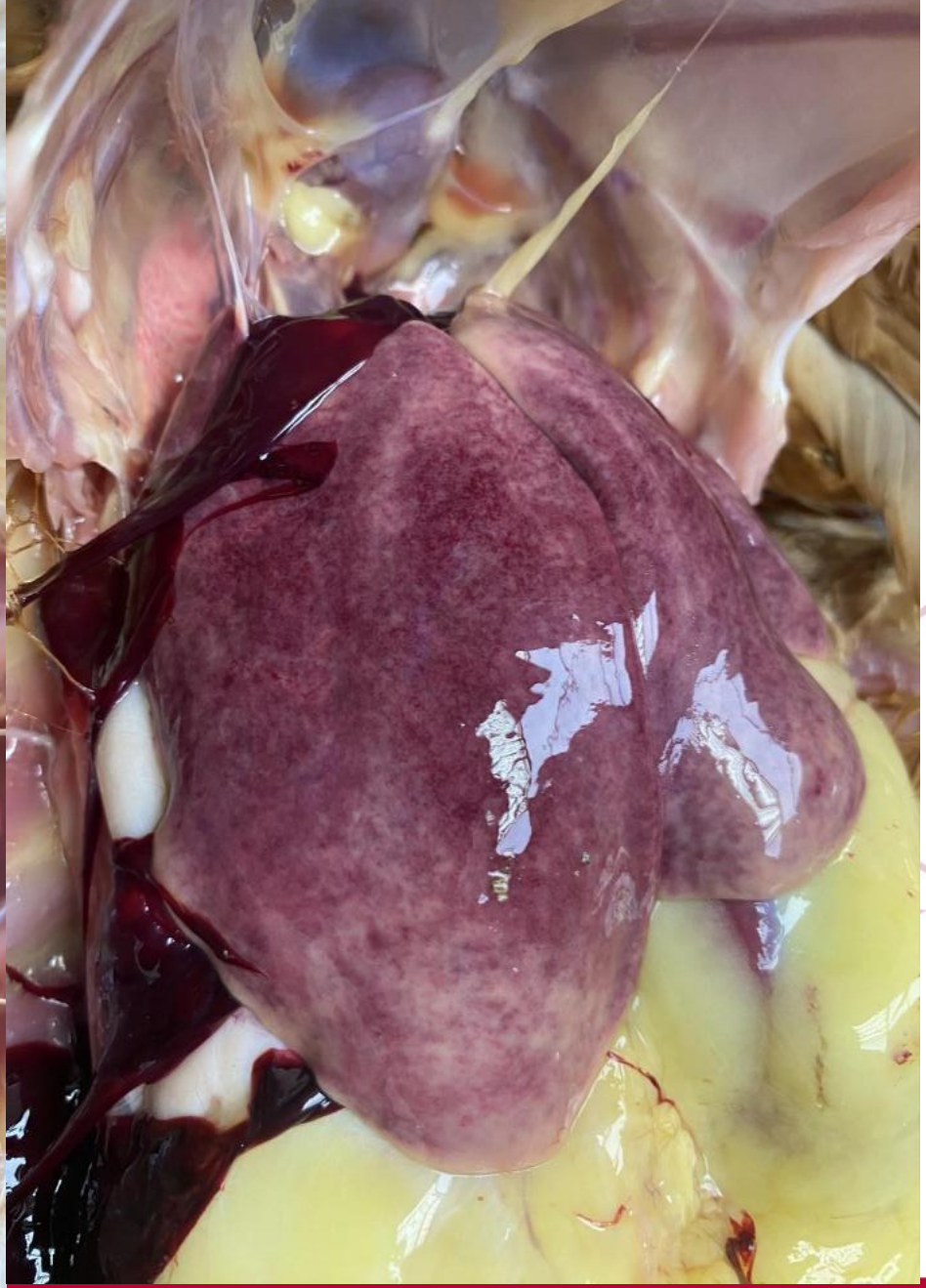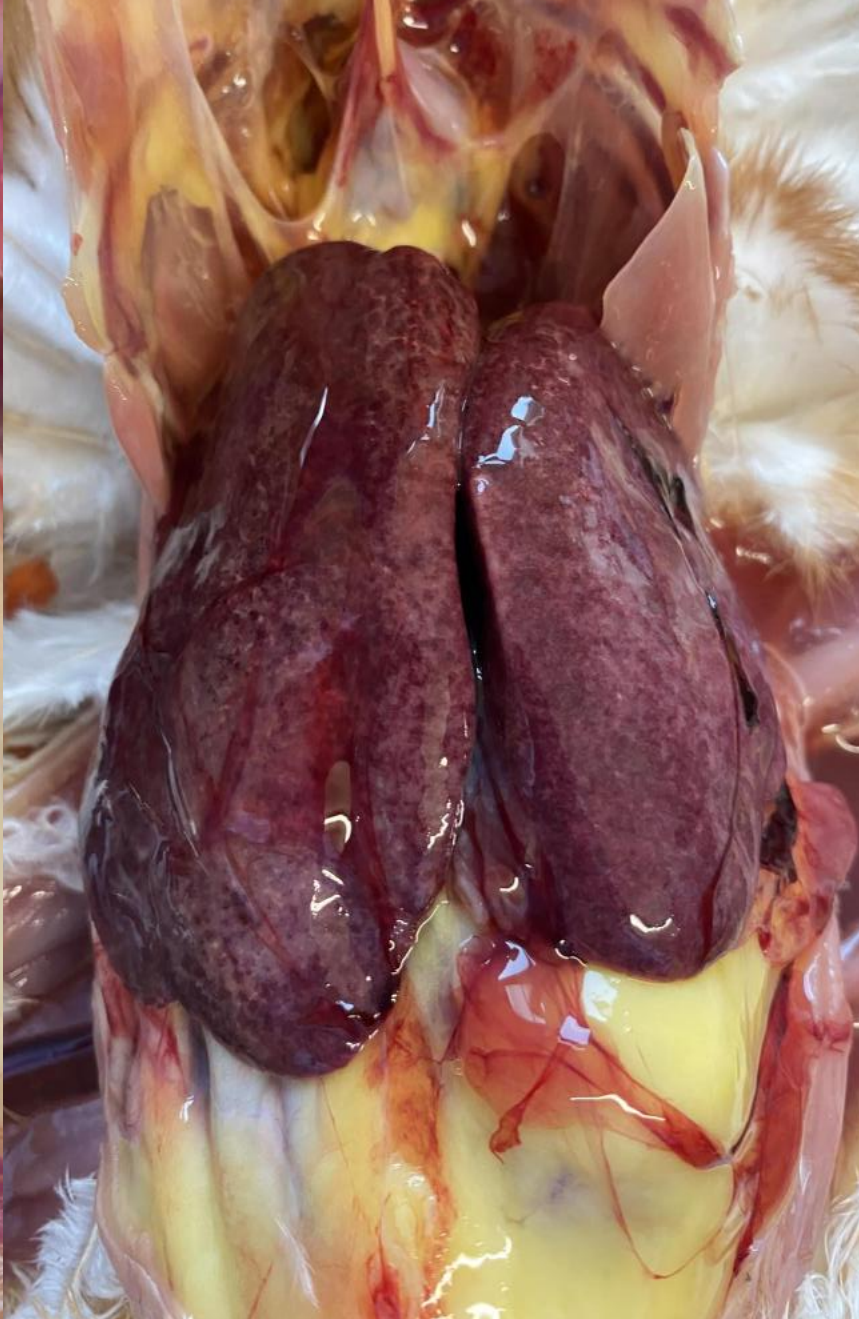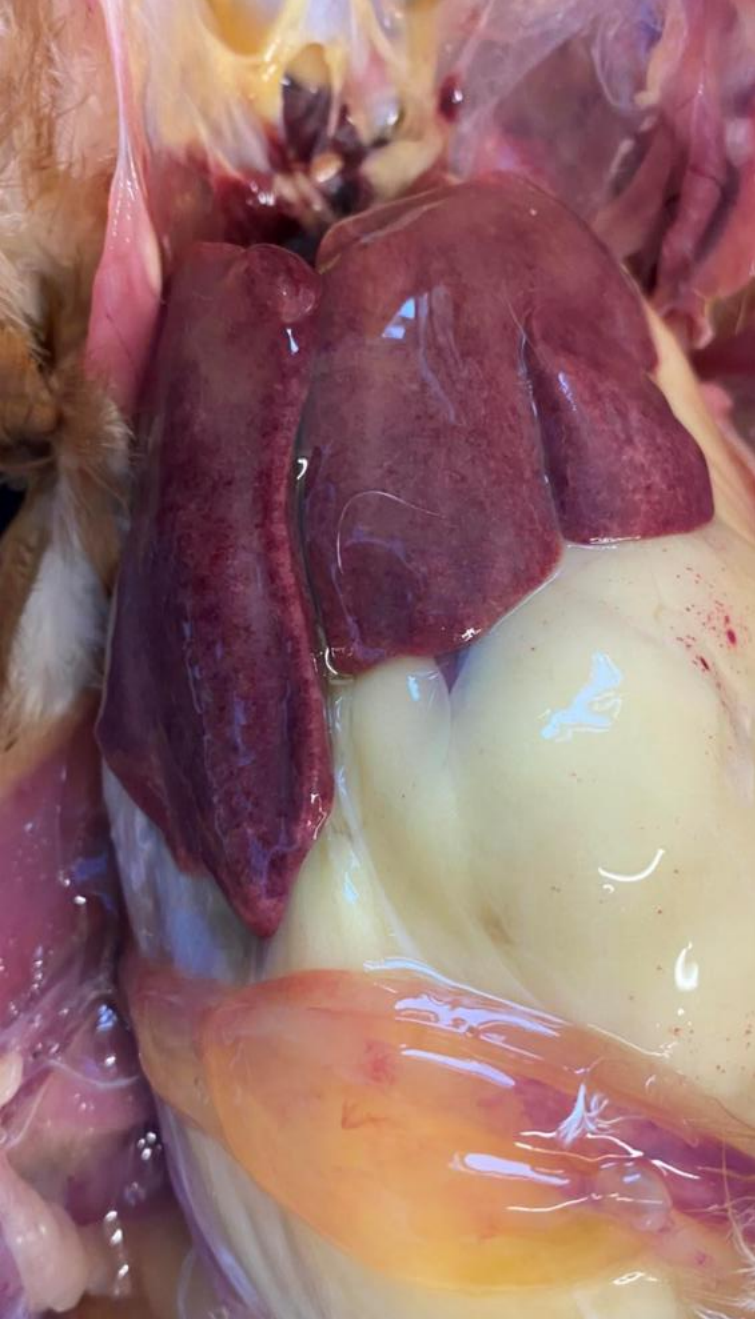- Production 89% average across the site
- Feed and water intake reported to have remained consistent in all houses
- Wormer course finished 24 hours ago
- Mortality at 10-11 per house
- Farmer reported the birds appeared to look brighter and comb colour was improved
- Postmortem examination was carried out on 5 hens from each house



Postmortem examination findings


- Similar postmortem findings observed in all 3 houses
 - Pale carcass
 - Dark and congested liver with pulpy quality
 - Haemorrhagic fluid in abdomen
 - In lay
 - large fat pad in 66% of the birds





Further diagnostic investigations

- Bacteriology culture from Liver, Kidney and abdominal fluid yielded no growth
- Histopathology results from liver samples showed acute, multifocal parenchymal haemorrhage.
- Comment from the histopathologist: 'The cause of these haemorrhages is not known. Fatty liver haemorrhagic syndrome is a possibility.'



Plan of action and follow up

- **Liver support** → All houses given Hepamix® for 5 days through the water
- Mortality returned to expected levels within 3-4 days
- Production increased back to 93% by week 54
- Current production parameters:
 - 66 weeks old
 - 90% production across the site
 - 48% Large, 45% Medium, 4% XL
 - 1.2% seconds
 - Average weekly mortality H1 – 14, H2 – 8 and H3 - 6



Was the mortality caused by fatty liver syndrome already present and exacerbated by the additional mobilization of Fenbendazole in the liver?

Was the mortality a result of a potential intoxication due to reduced liver function?





**Thank you for
your attention!**
