

Role of histopathology in diagnosis of poultry diseases

Christopher Poulos and Catarina Guerreiro

APHA Lasswade





Contents

I. Introduction

II. Sampling, fixation, dispatch

III. Making the diagnosis

IV. Viral diseases

V. Parasitic diseases

VI. Bacterial diseases

VII. Fungal diseases

VIII. Concluding comments



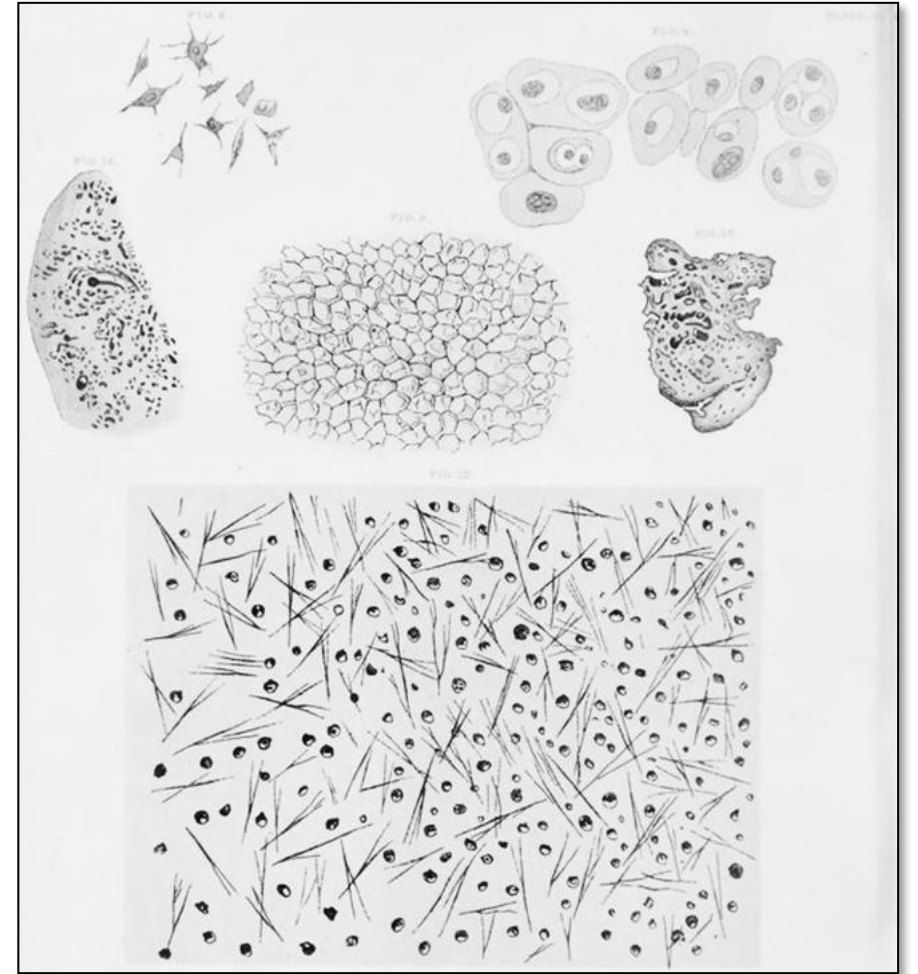


Introduction

Histopathology has been around for over 180 years.

Still a valuable diagnostic tool for all species, including poultry.

APHA Lasswade continues a proud tradition as a specialised centre for poultry histopathology.

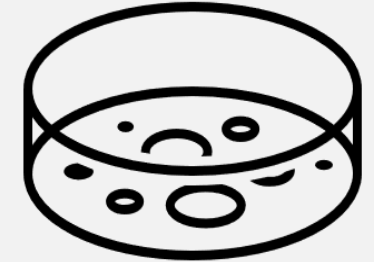

Johannes Müller, *On the Nature and Structure Characteristics of Cancer* (1838)

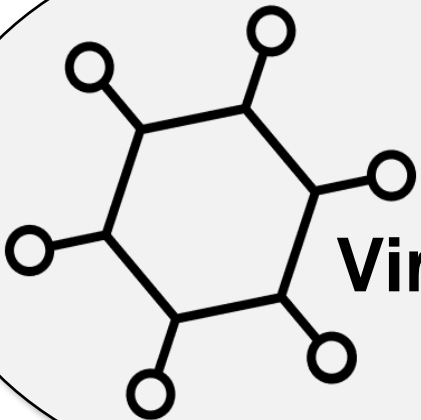


Techniques for disease investigation

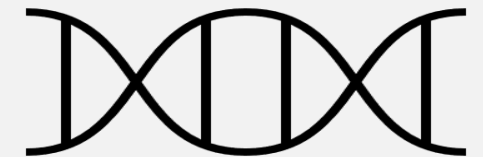Histopathology



Bacteriology



Virology



Sequencing

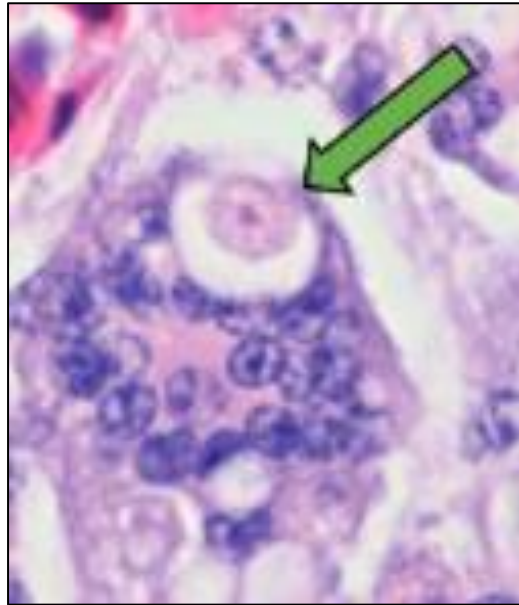


Surveillance of GB poultry diseases

APHA histopathology significantly contributes to poultry disease surveillance in Great Britain.

VetRecord Surveillance

October 2023
Histomonosis
11w turkey

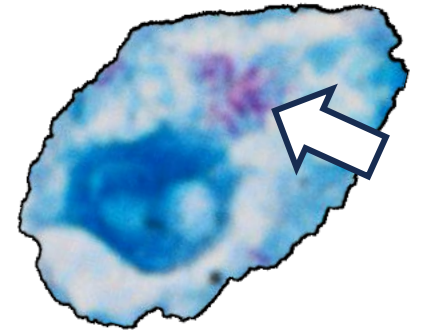


[Non-commercial, small flock dashboard | Tableau Public](#)

Search years: 2020-2024

| | |
|---------------------------|----------------|
| Avian tuberculosis | 8 cases |
|---------------------------|----------------|

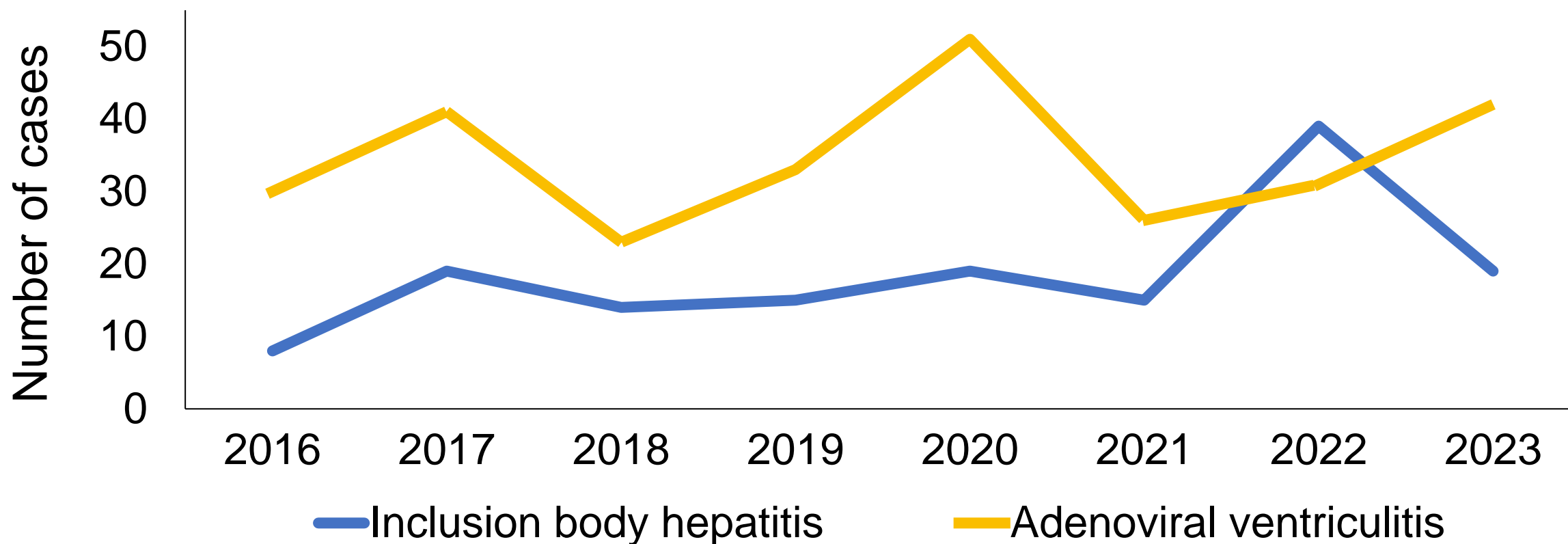
Macrophage with
acid-fast bacteria in
cytoplasm (arrow)





Veterinary Investigation Diagnosis Analysis reports

| Diagnosis name | VIDA number |
|-----------------------------------|-------------|
| Inclusion body hepatitis | 874 |
| Gizzard erosion due to Adenovirus | 268 |





Sample collection and fixation

Good fixation is essential to preserve cellular architecture of tissues

Formalin as 10% NBF or formol saline

- ~1-2 cm / day penetration
- Can be slower with cold

Fixation optimisation

- < 1 cm thick
- 1:10 (tissue : formalin) ratio

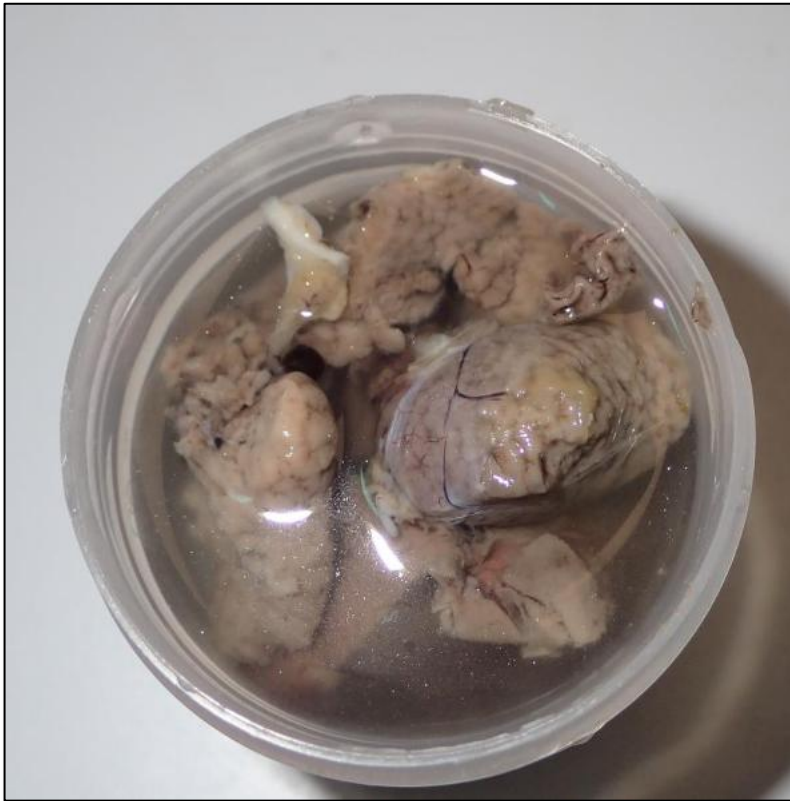

Other brands available.

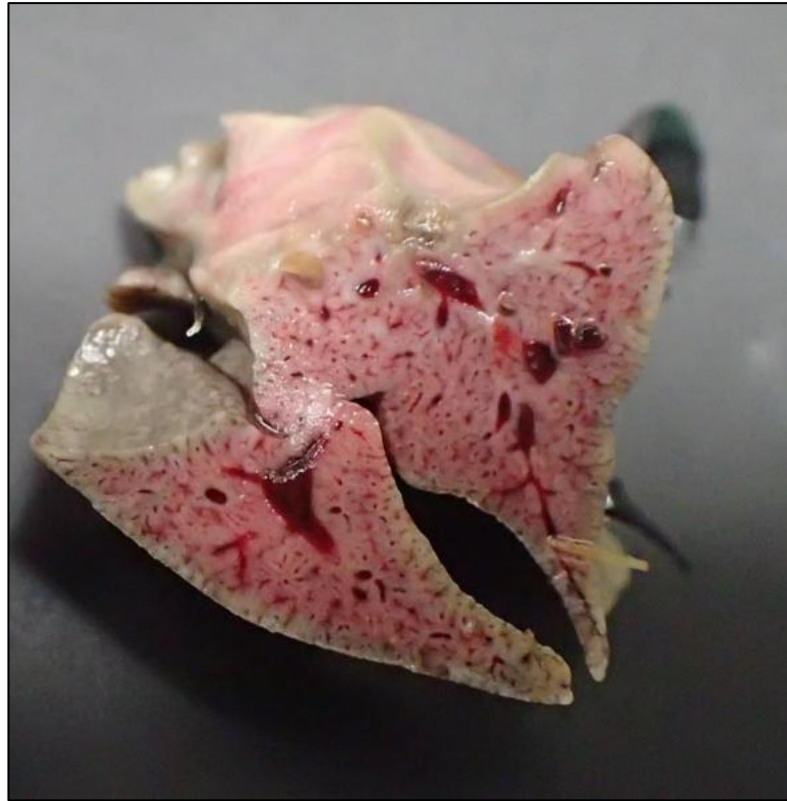

Fixation and dispatch

Too much tissue,
too little formalin.



Medium-rare, needs more
fixation with smaller sections.

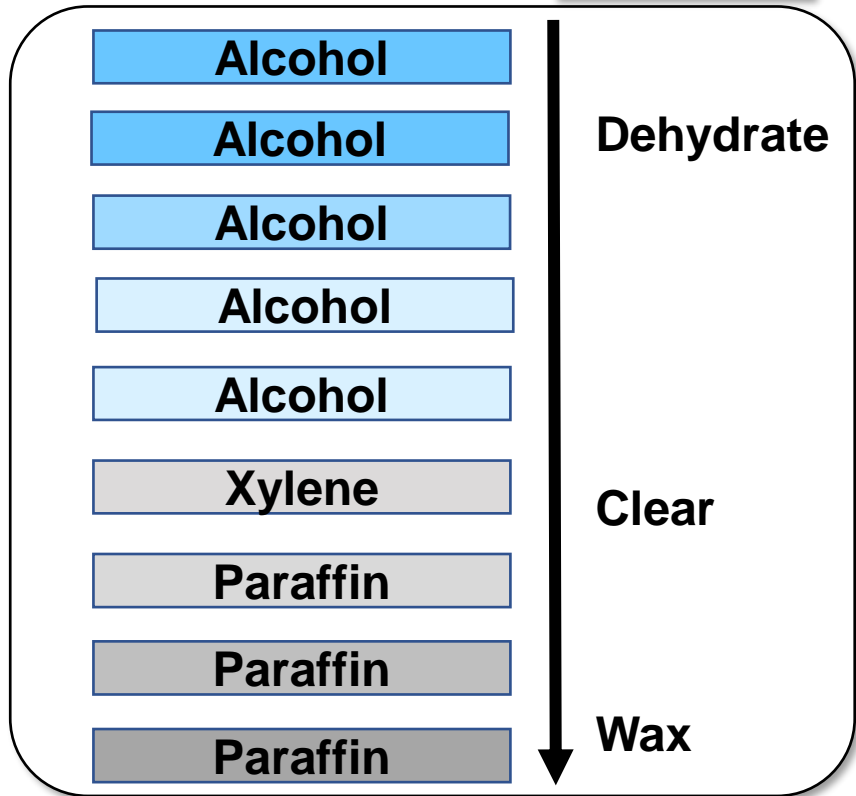


Well-done,
Bon Appetit.

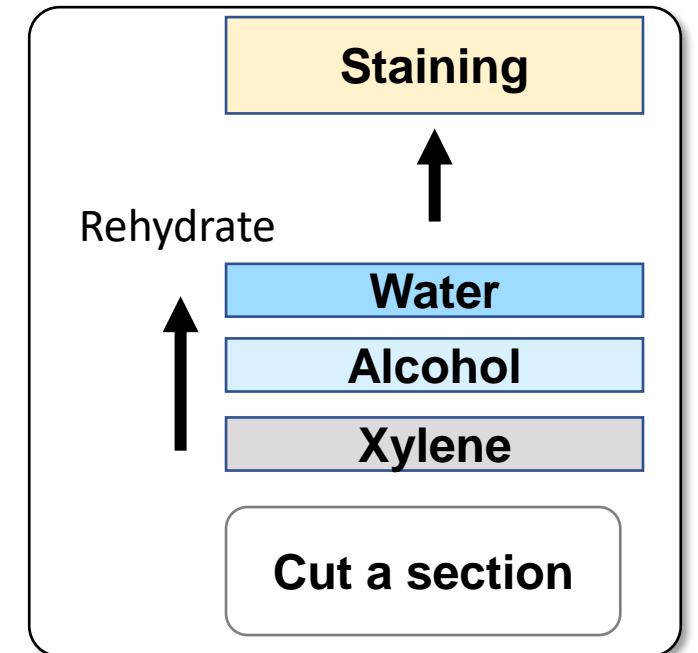
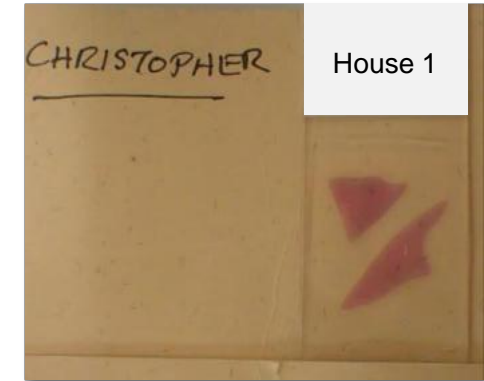


Processing / slide generation

Tissue processing



Making a slide

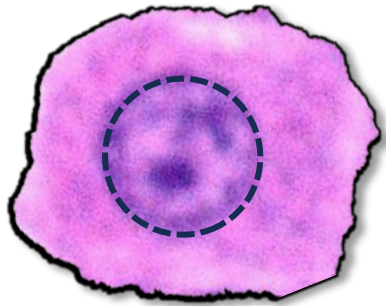




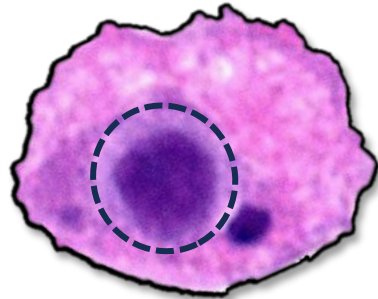

Can everything be diagnosed?

Diagnosis by histopathology can be straight-forward...

Inclusion body hepatitis

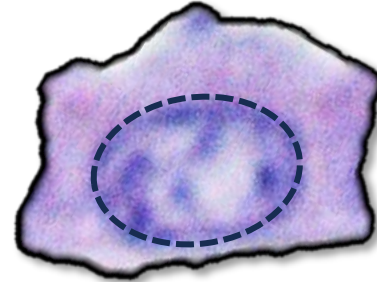


Normal
hepatocyte

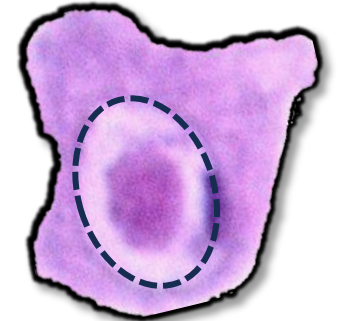


Hepatocyte with
intranuclear
inclusion body

Adenoviral ventriculitis



Normal
epithelial cell



Epithelial cell
with intranuclear
inclusion body

The nuclear membrane in above cells is outlined by a dashed line.

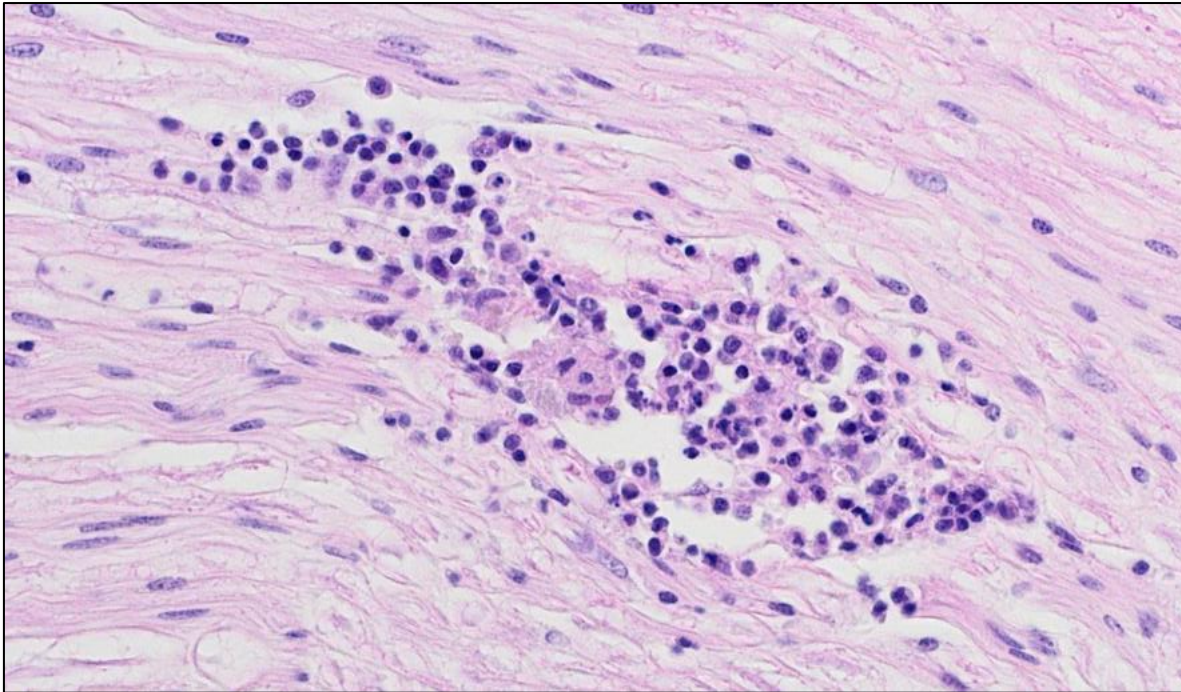


Can everything be diagnosed?

...or it can be more complex and require further testing.

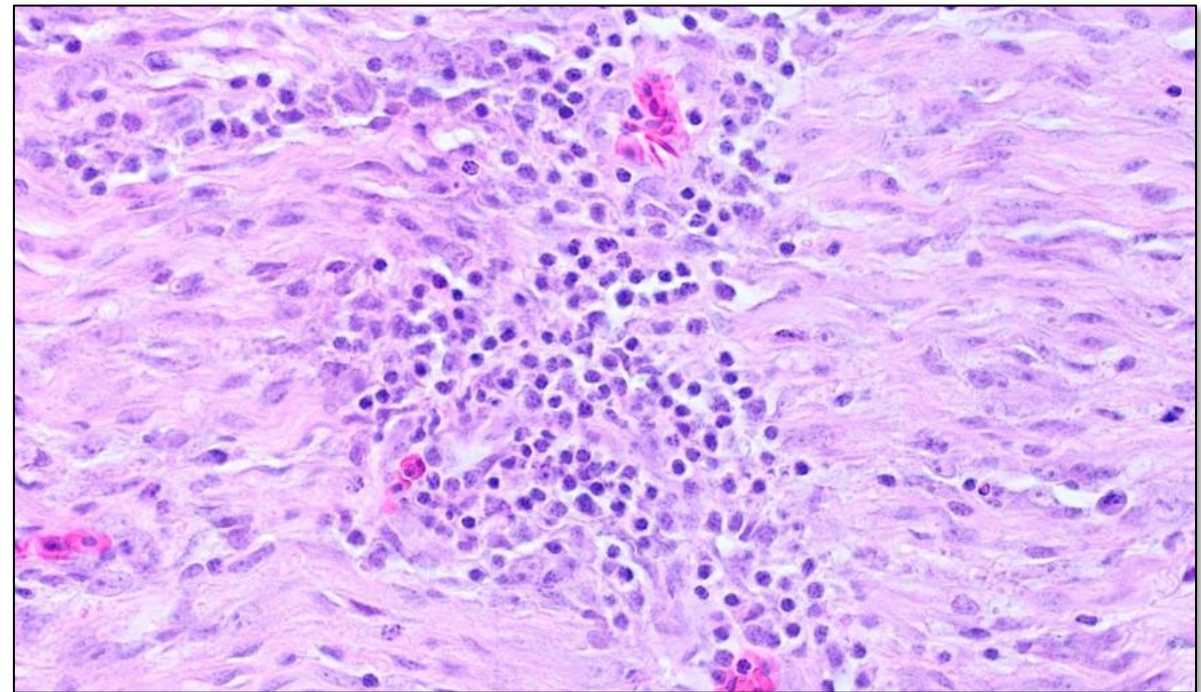
Marek's disease (MDV+ PCR)

Sciatic nerve, small flock chicken



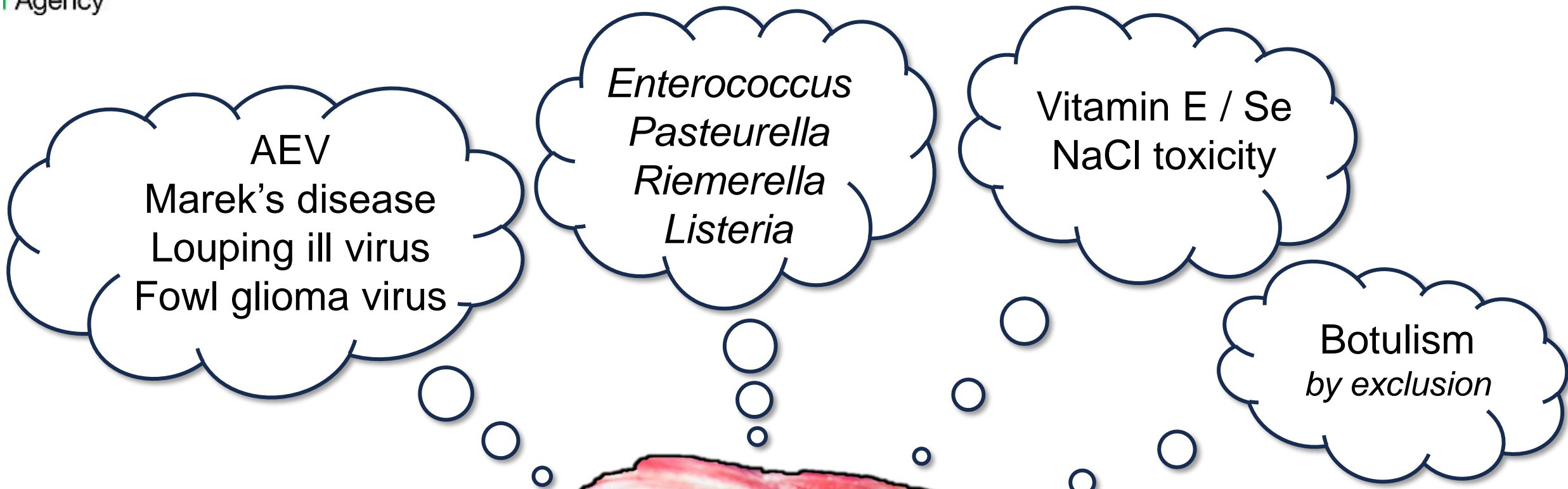
Peripheral neuritis (MDV- PCR)

Sciatic nerve, small flock chicken

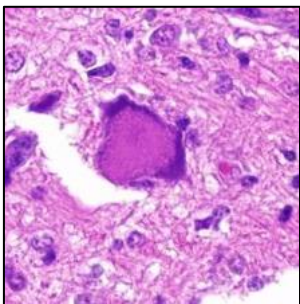




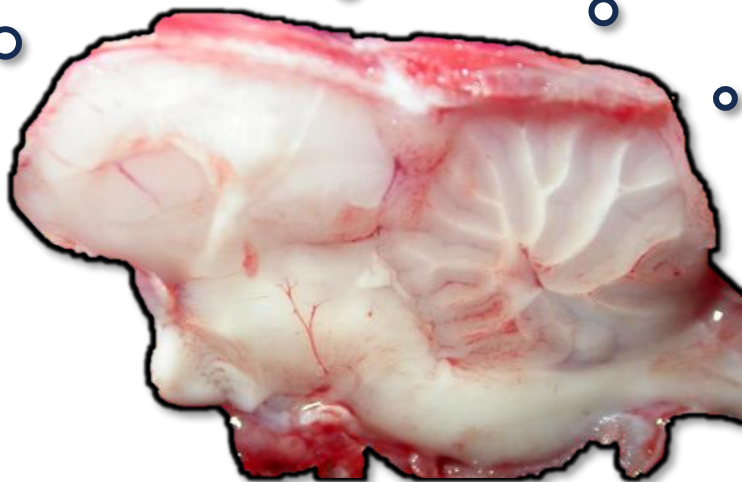
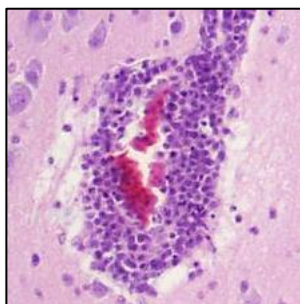
Differential diagnoses by histopathology



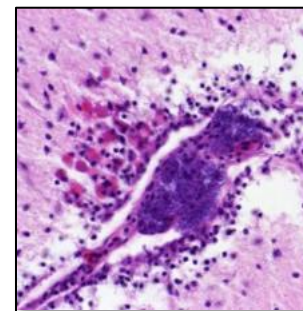
Chromatolysis



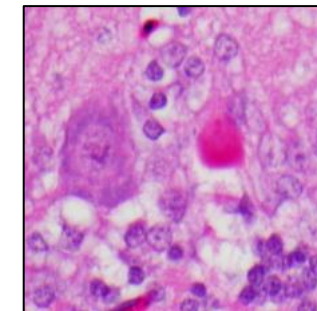
Cuffing



Bacteria

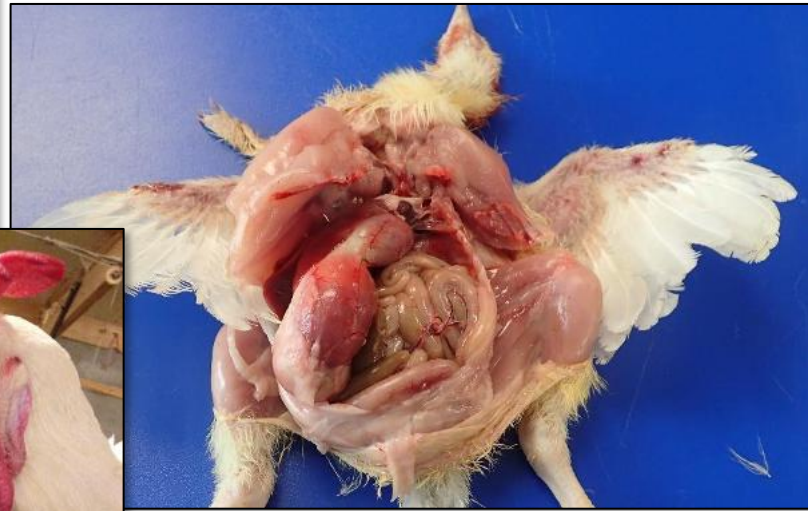

Necrosis





And now we will see select examples on how histopathology can be used to diagnose common poultry diseases...





Diagnosis of viral diseases

ILT

IBH

Adenoviral
ventriculitis

Histopathology is very good for diagnosis

Inclusion bodies

TVP

IBD

IB-QX

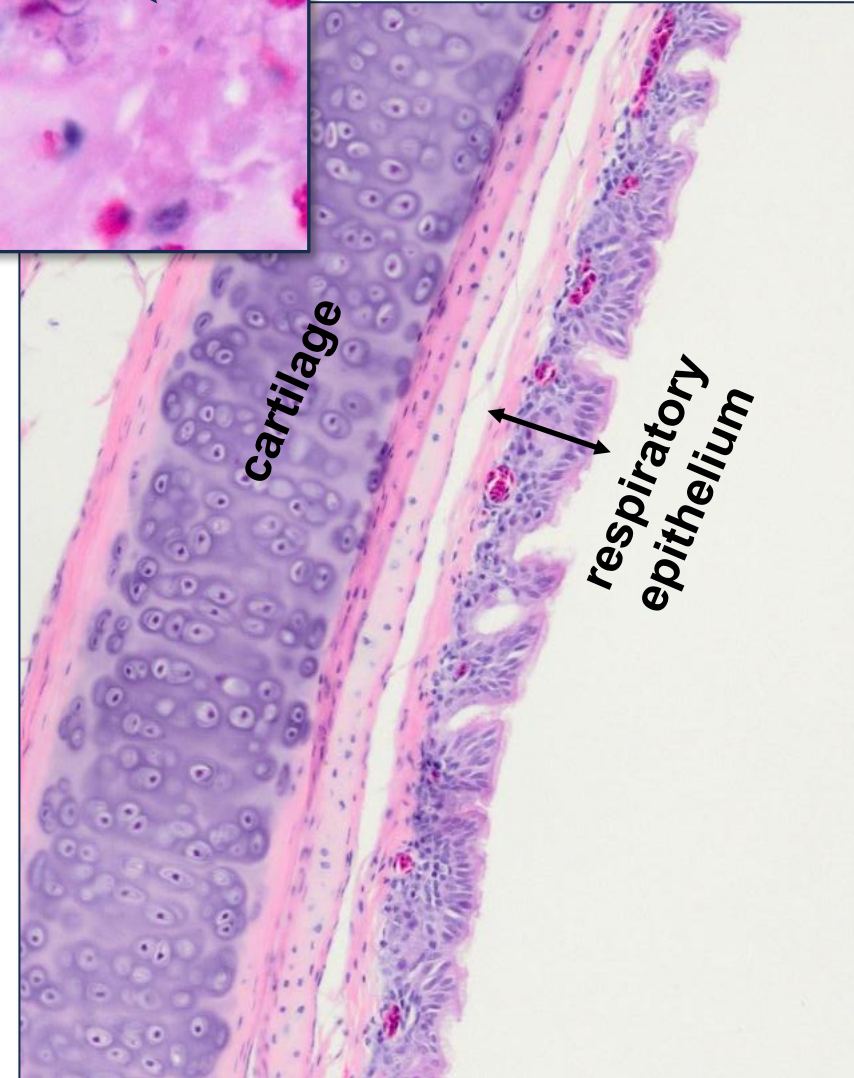
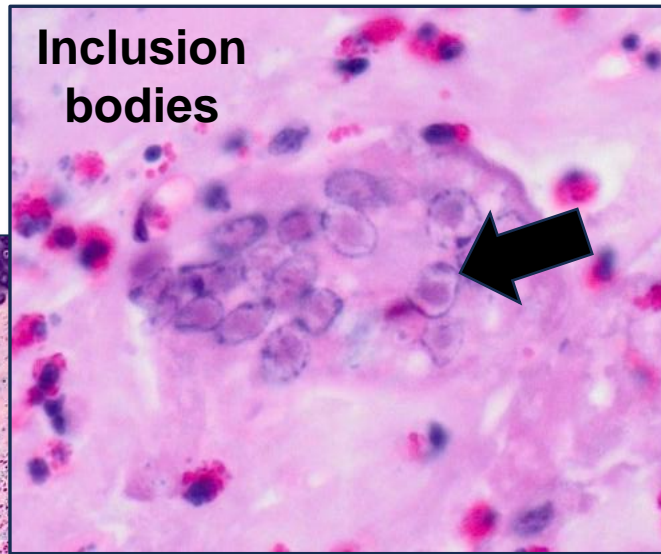
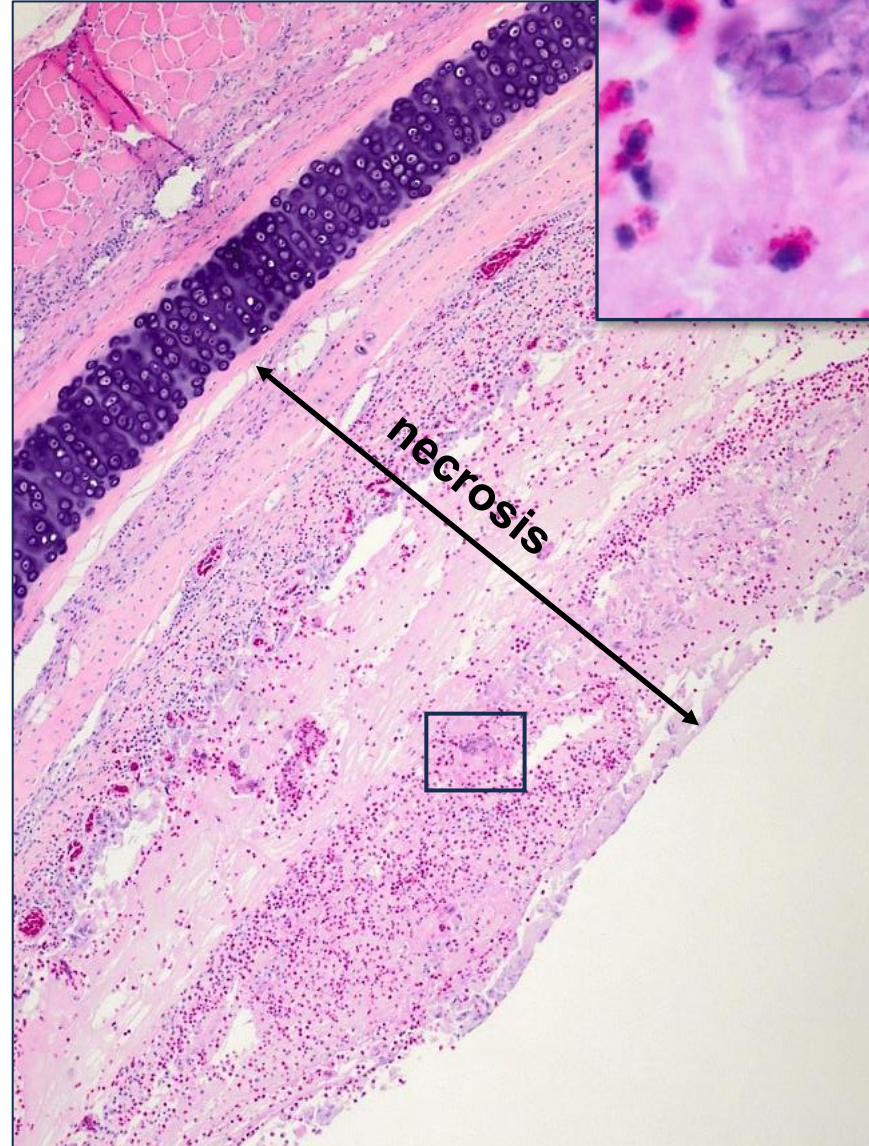
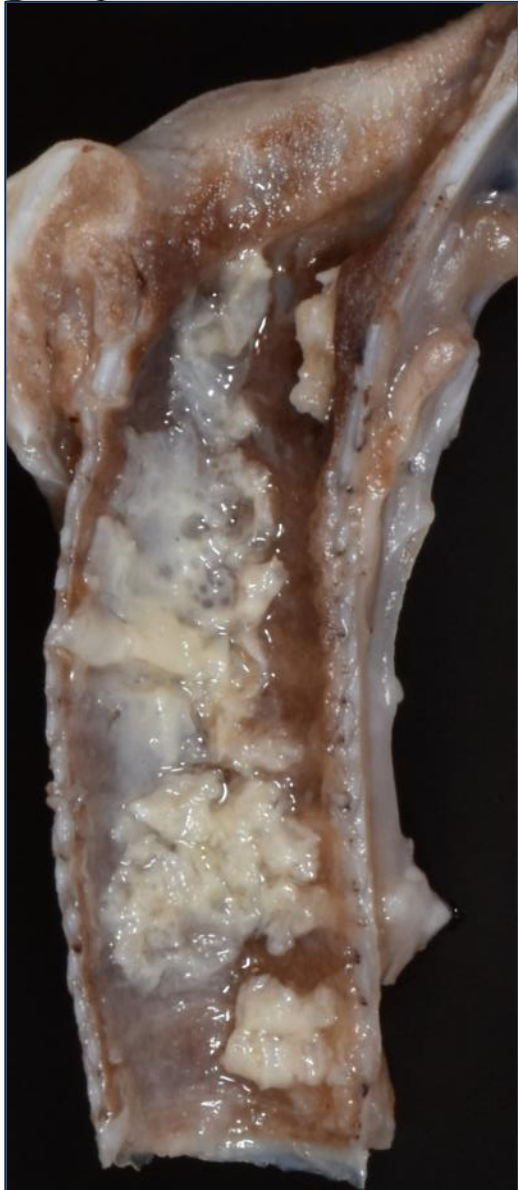Histopathology cannot always provide a
definitive answer

Non-specific, Suggestive of, Consistent with

PCR required for confirmation



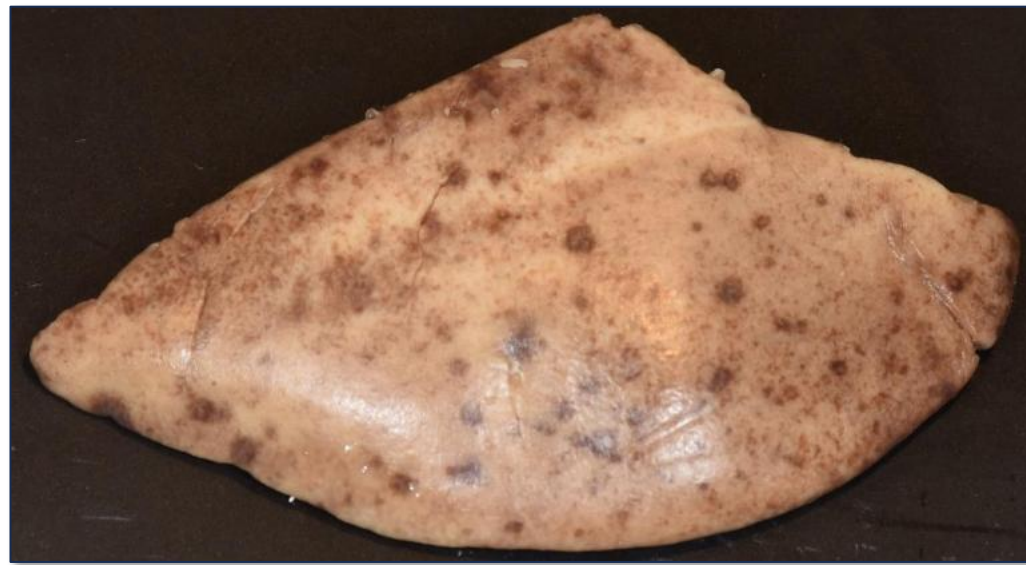ILT in a chicken *herpesvirus*





Animal &
Plant Health
Agency

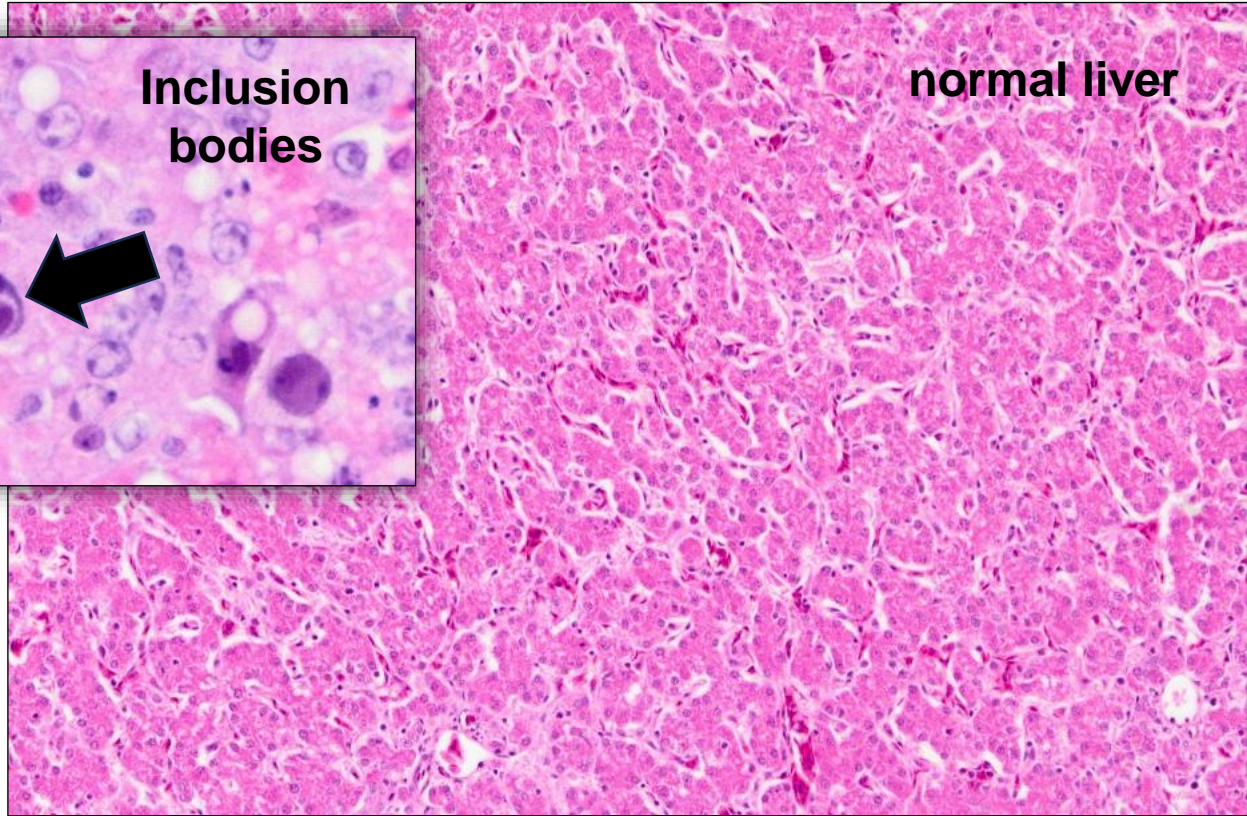
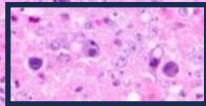
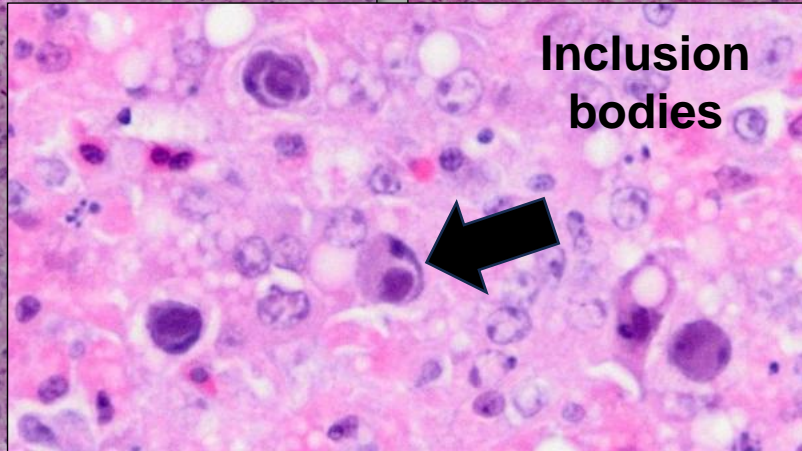
IBH in a chicken *adenovirus*



necrotic liver

Inclusion
bodies

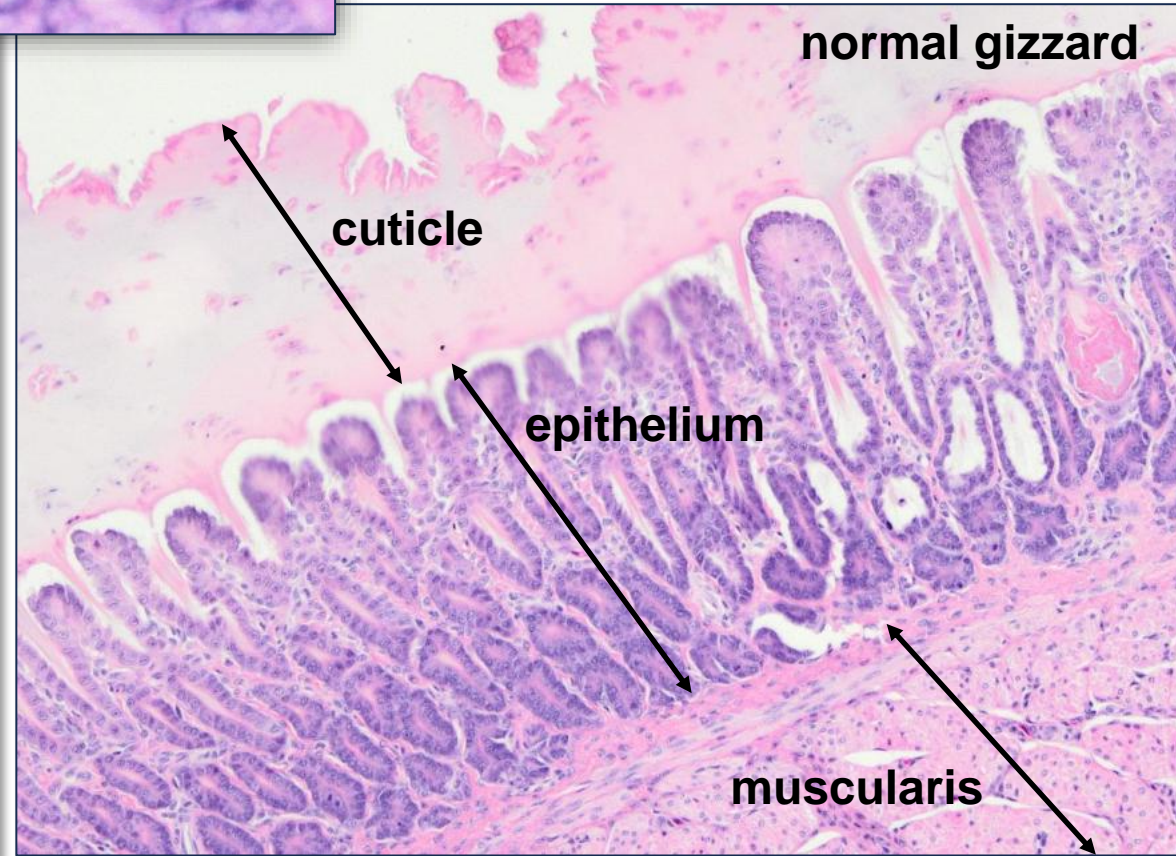
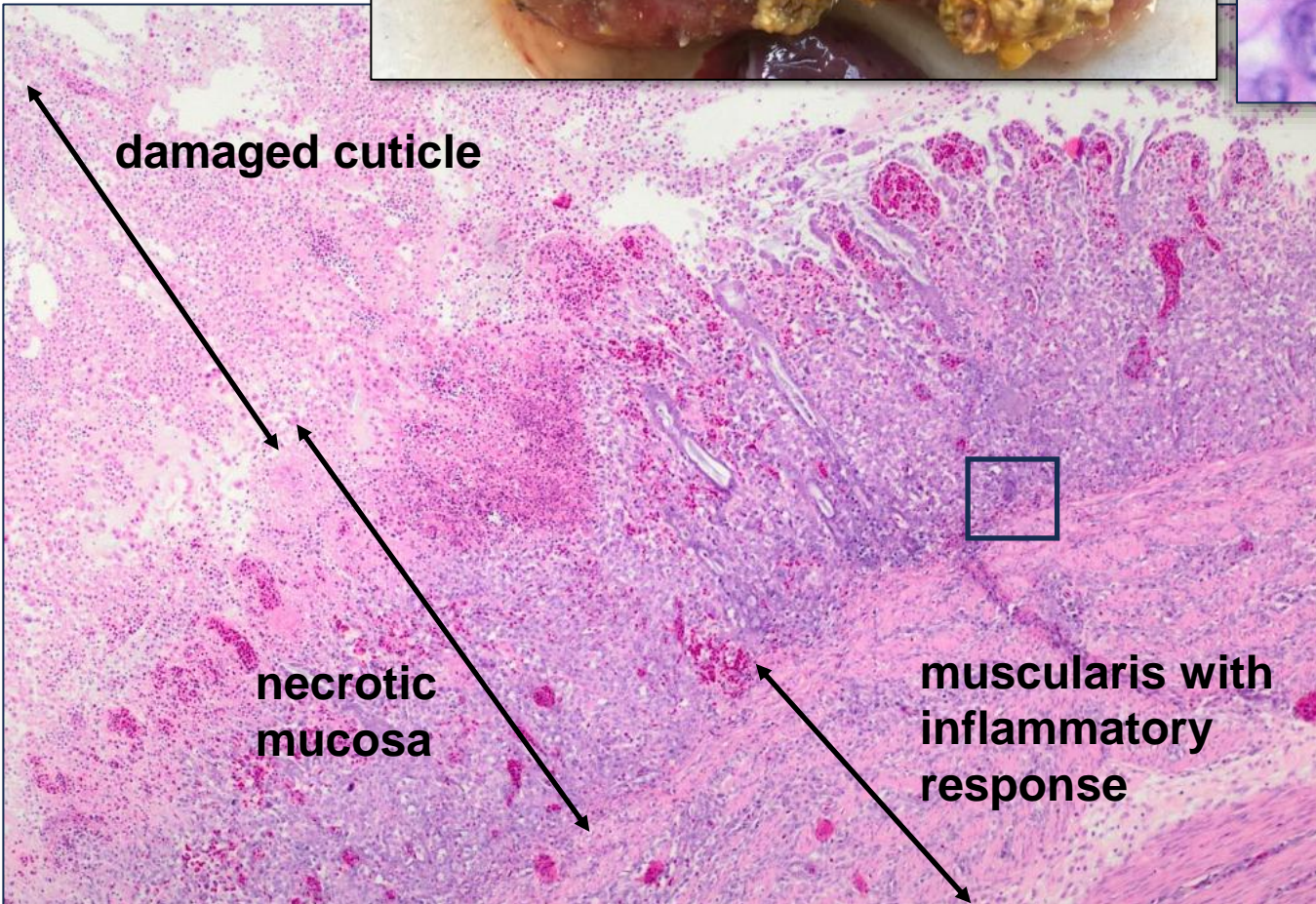
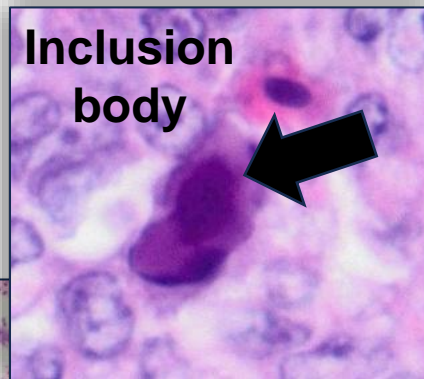
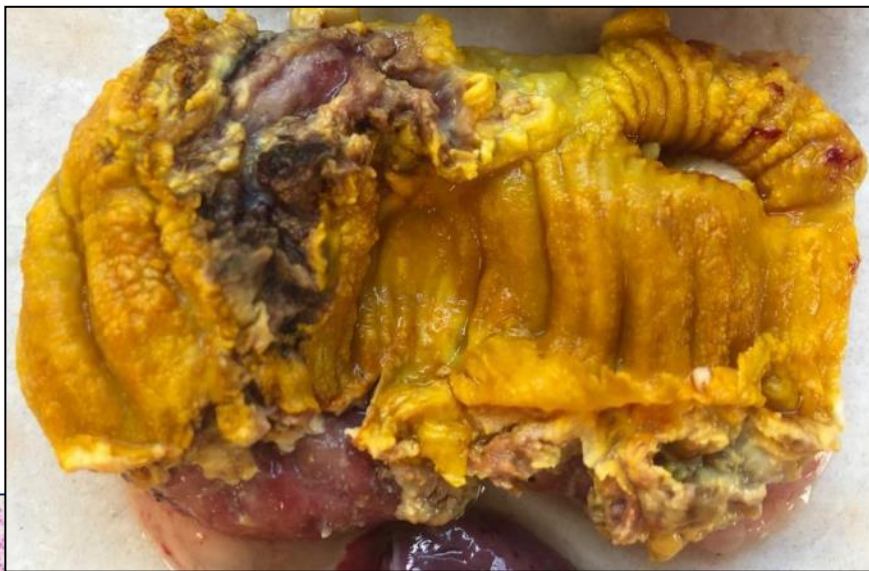normal liver





Animal &
Plant Health
Agency

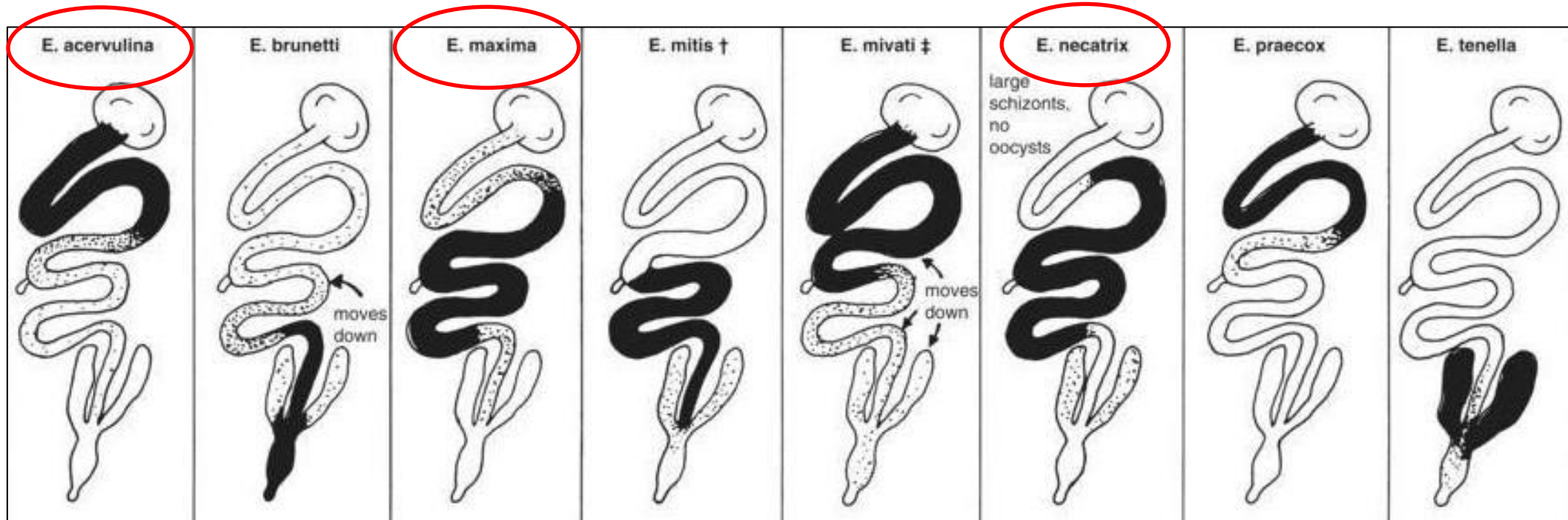
adenoviral ventriculitis in a chicken





Diagnosis of parasitic diseases

Coccidiosis



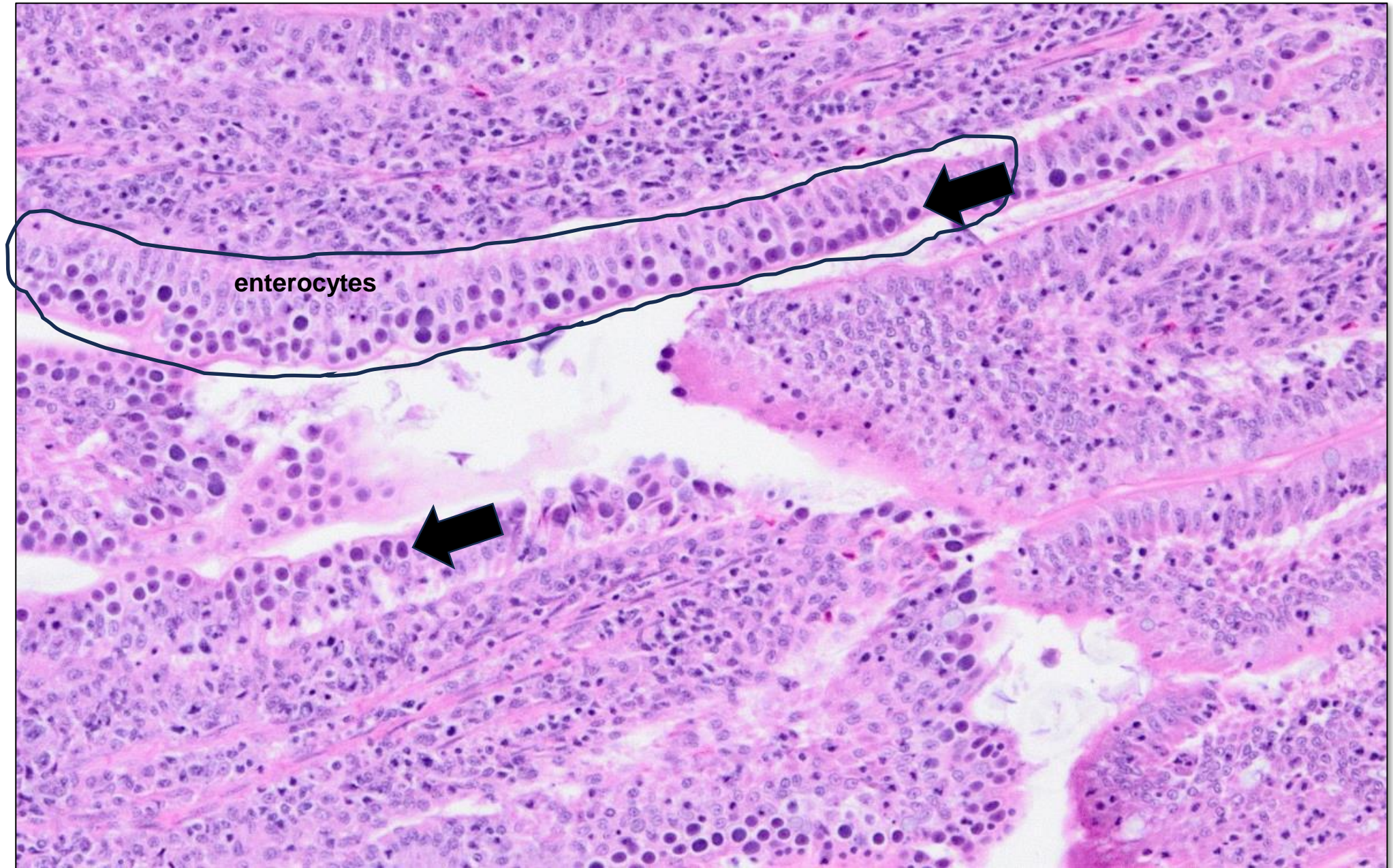
Adapted from: *Diseases of Poultry*, 12th edition

Keep an open mind!

Unlike faecal counts, histopathology can detect early coccidial stages and not only oocysts

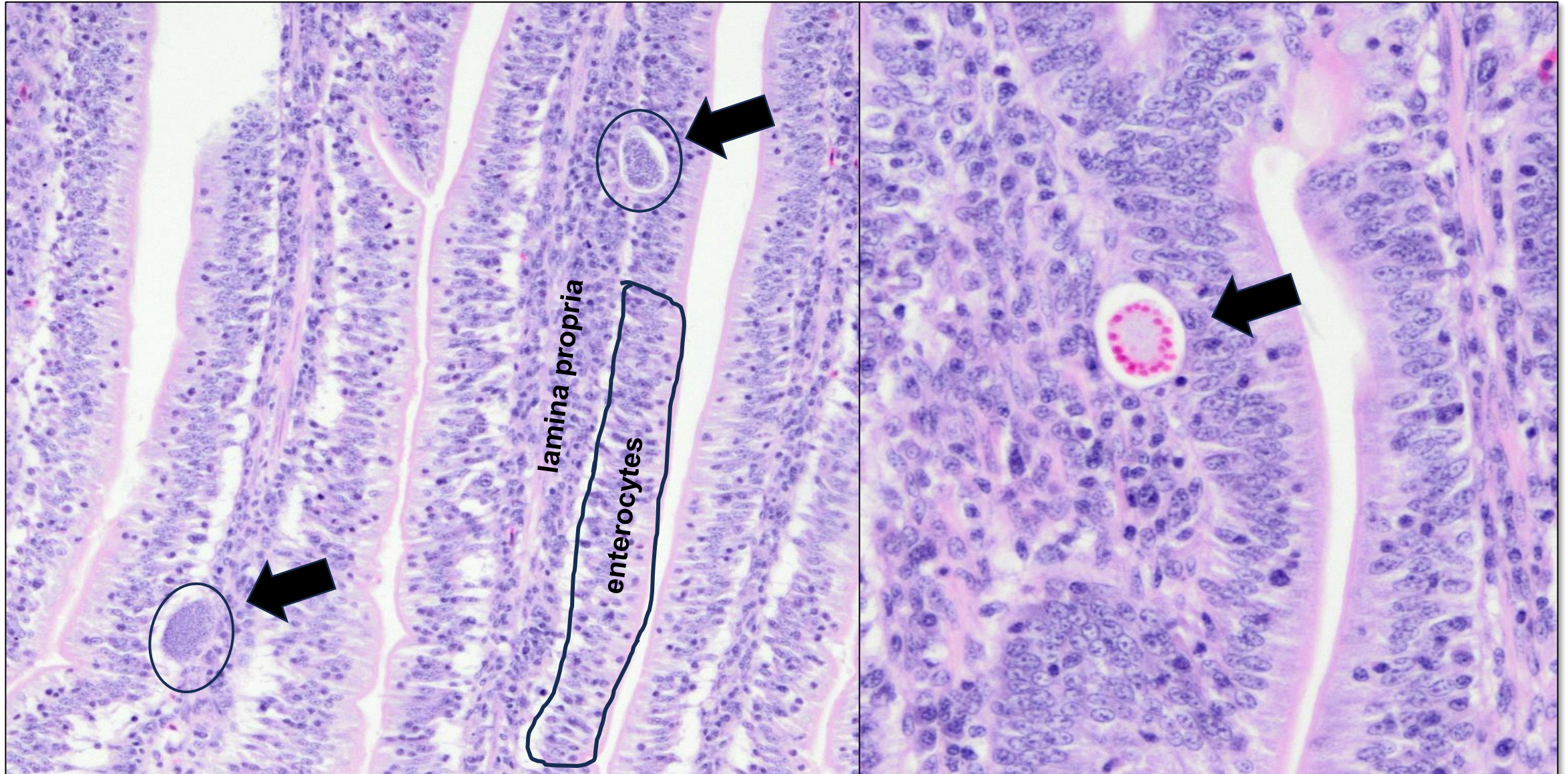


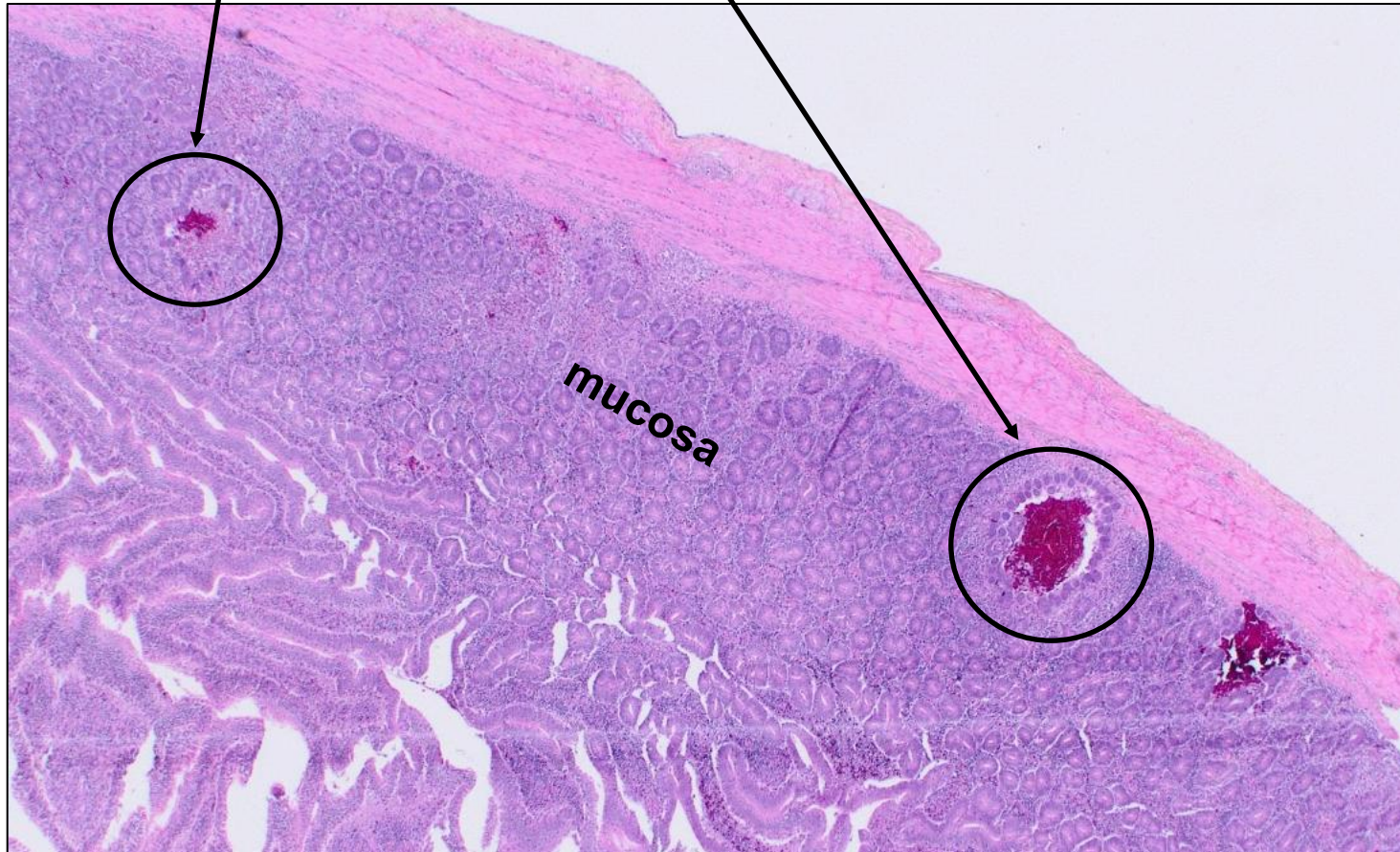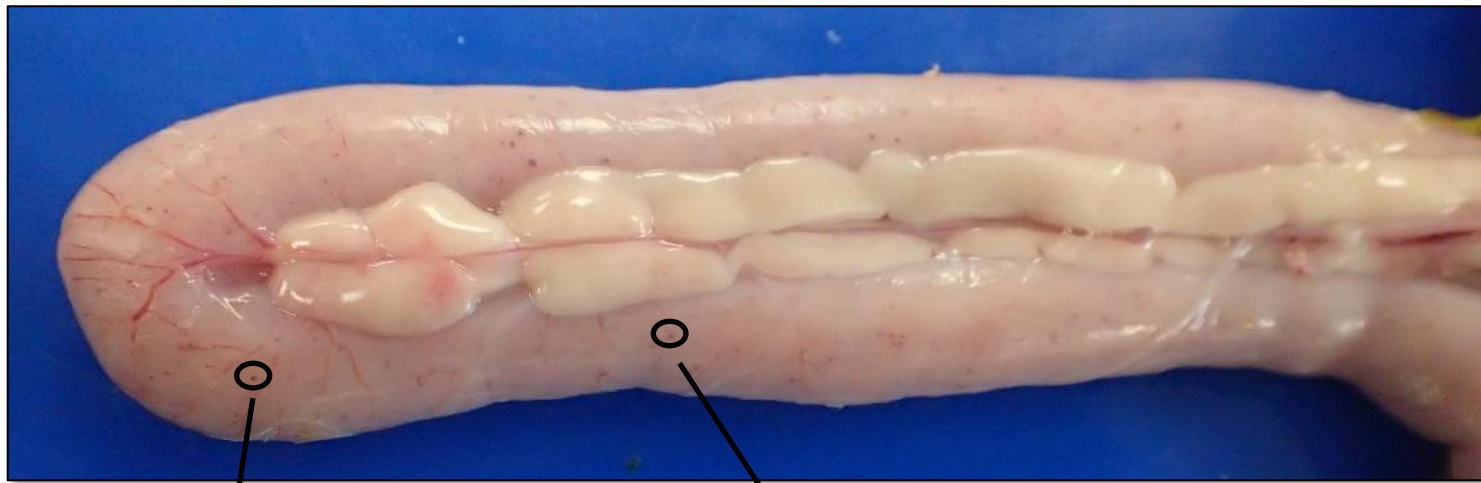
Duodenum of a chicken: *Eimeria acervulina*





Mid intestine of a chicken: *Eimeria maxima*



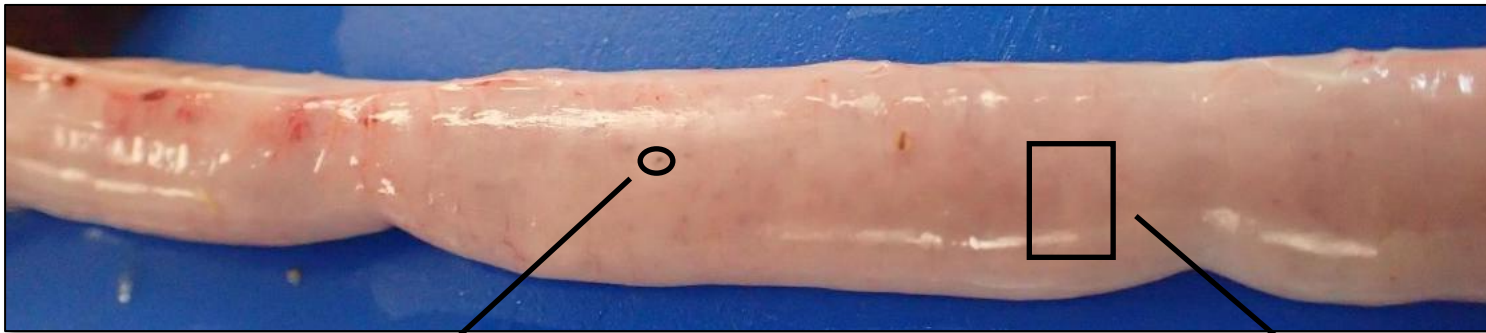


**Duodenum of a
chicken
*Eimeria necatrix***

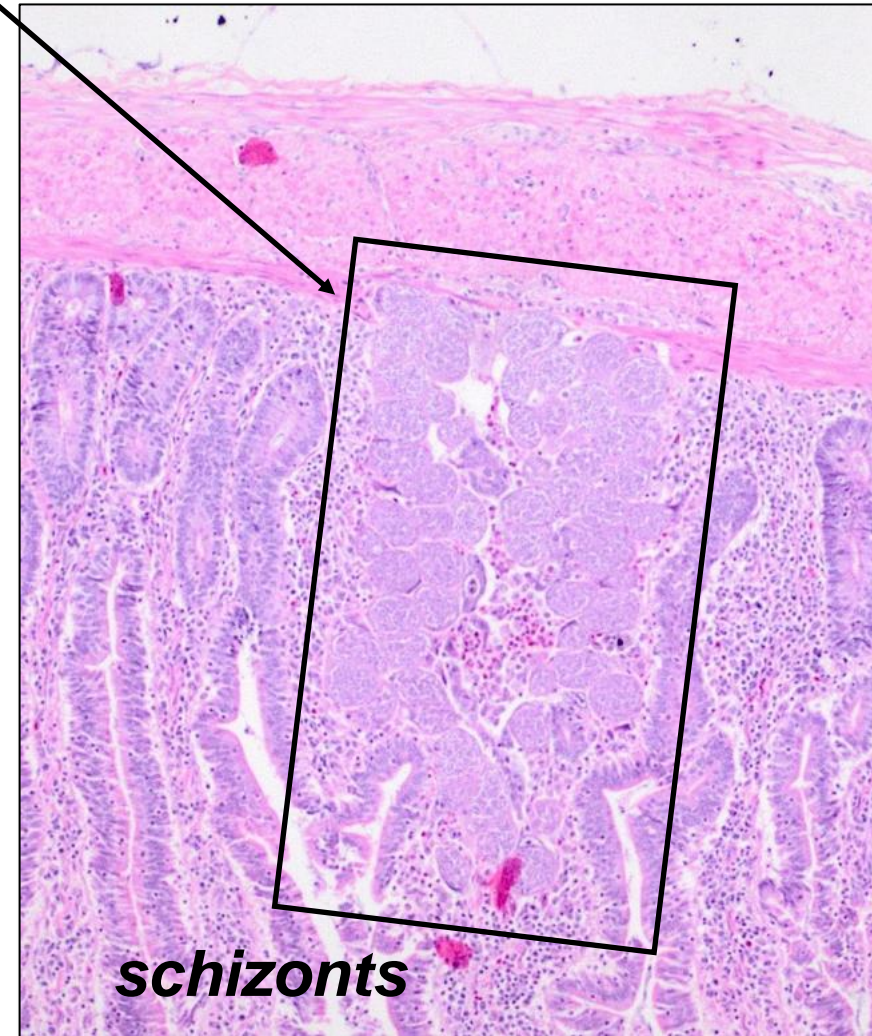
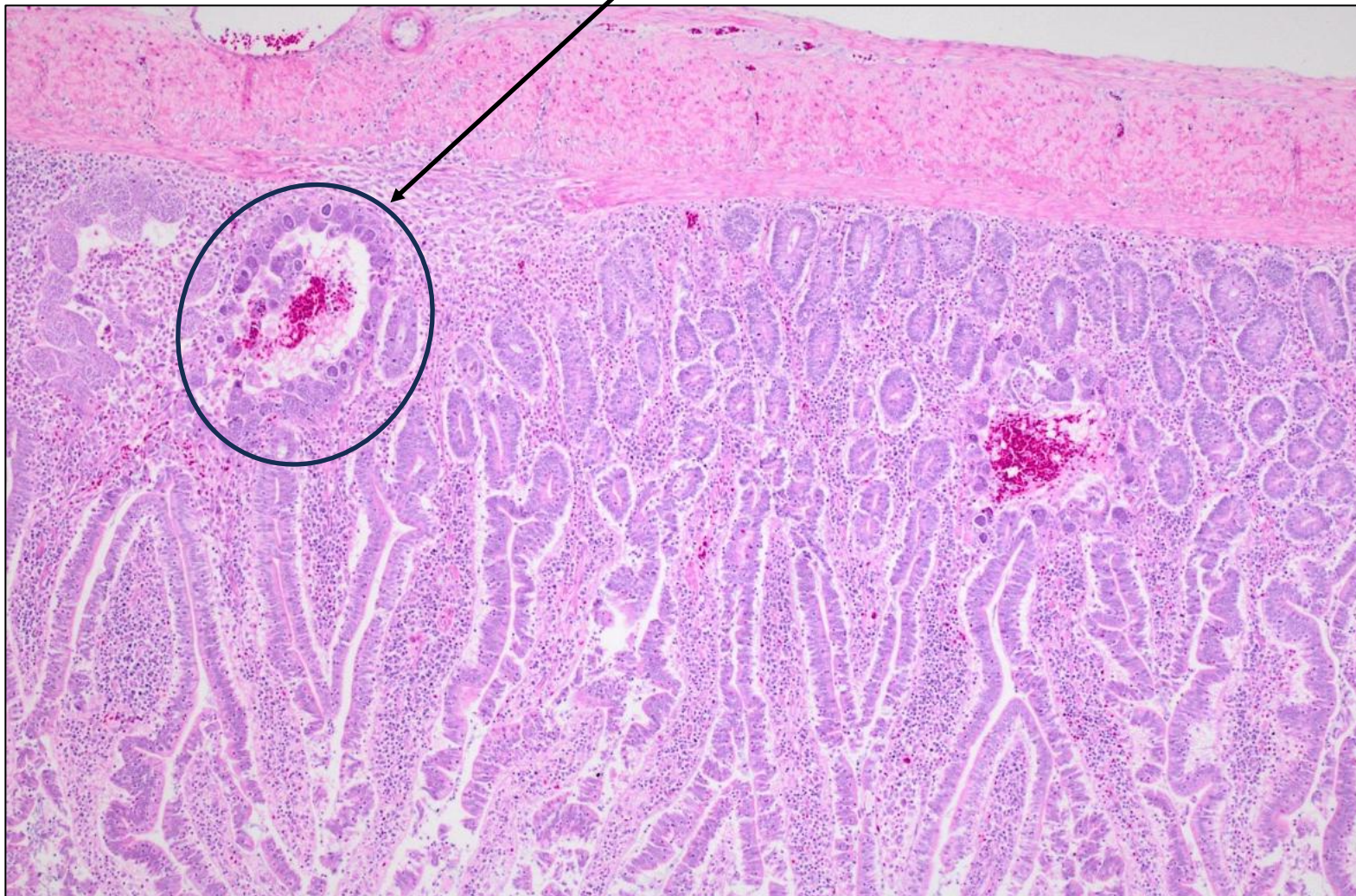
**❖ Example of an
unexpected
location**



Animal &
Plant Health
Agency



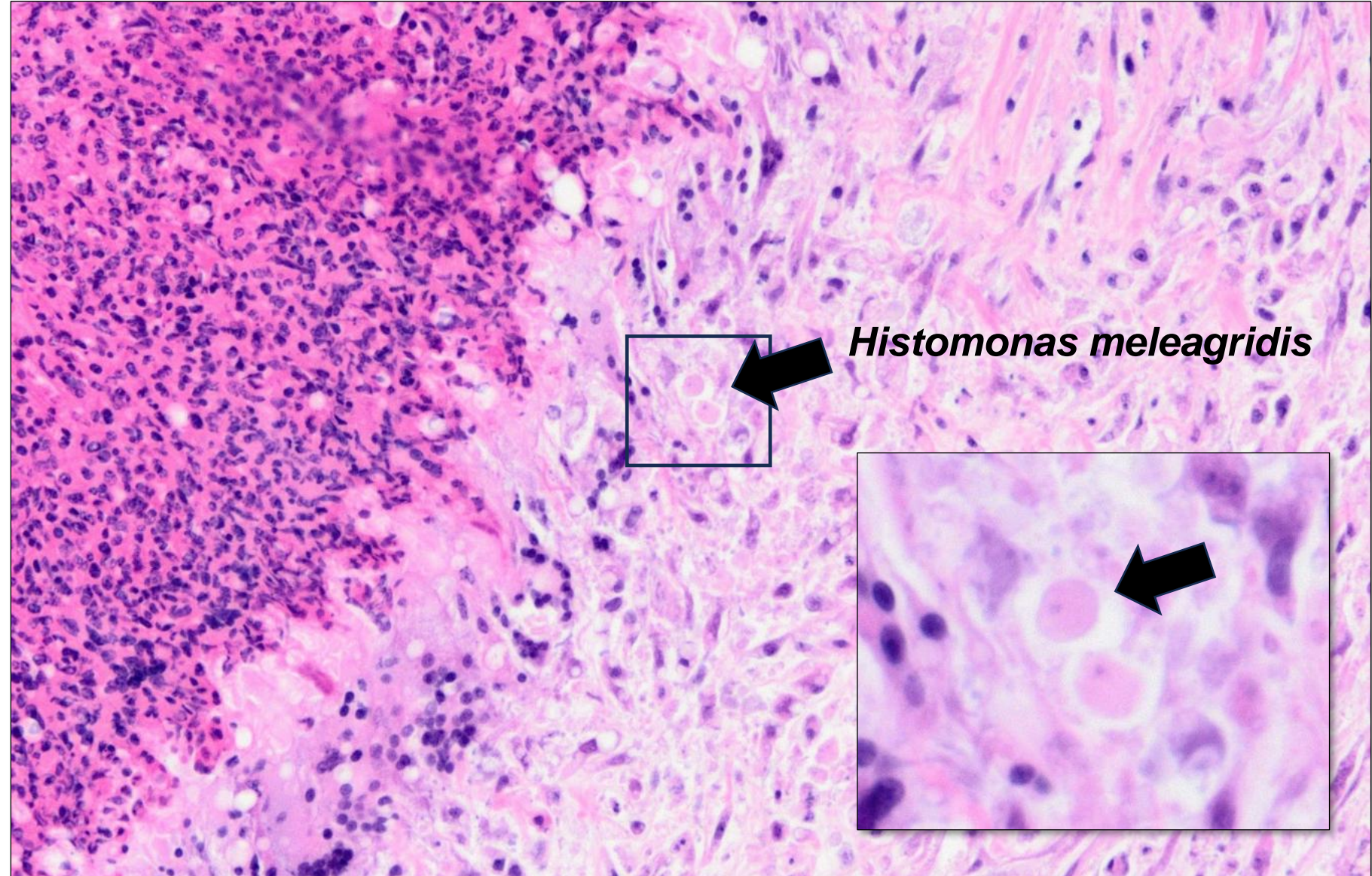
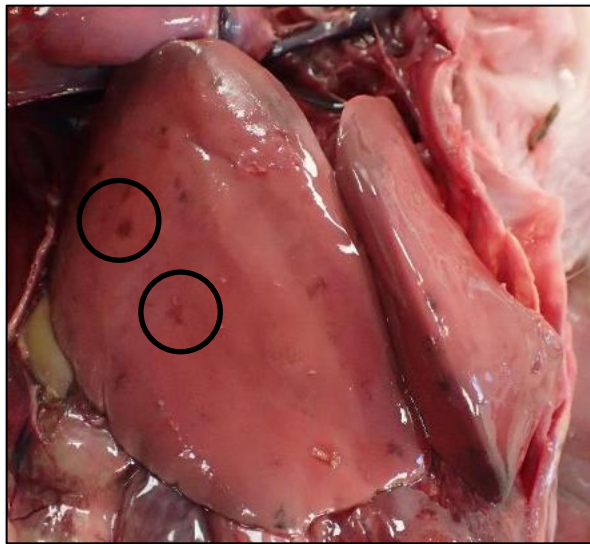
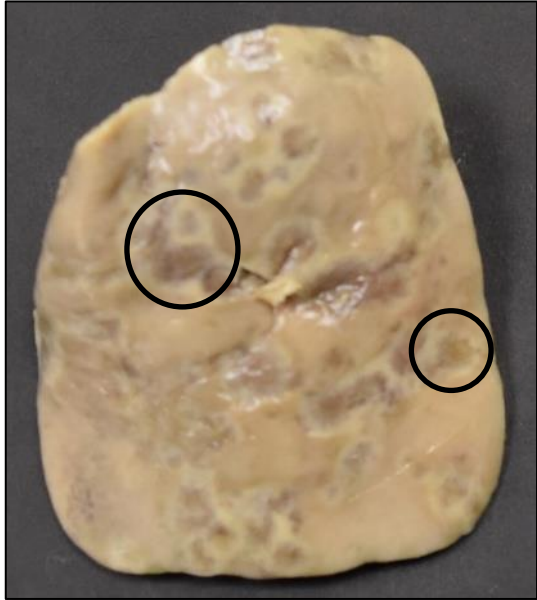
Jejunum of a chicken
Eimeria necatrix
"salt and pepper"



schizonts

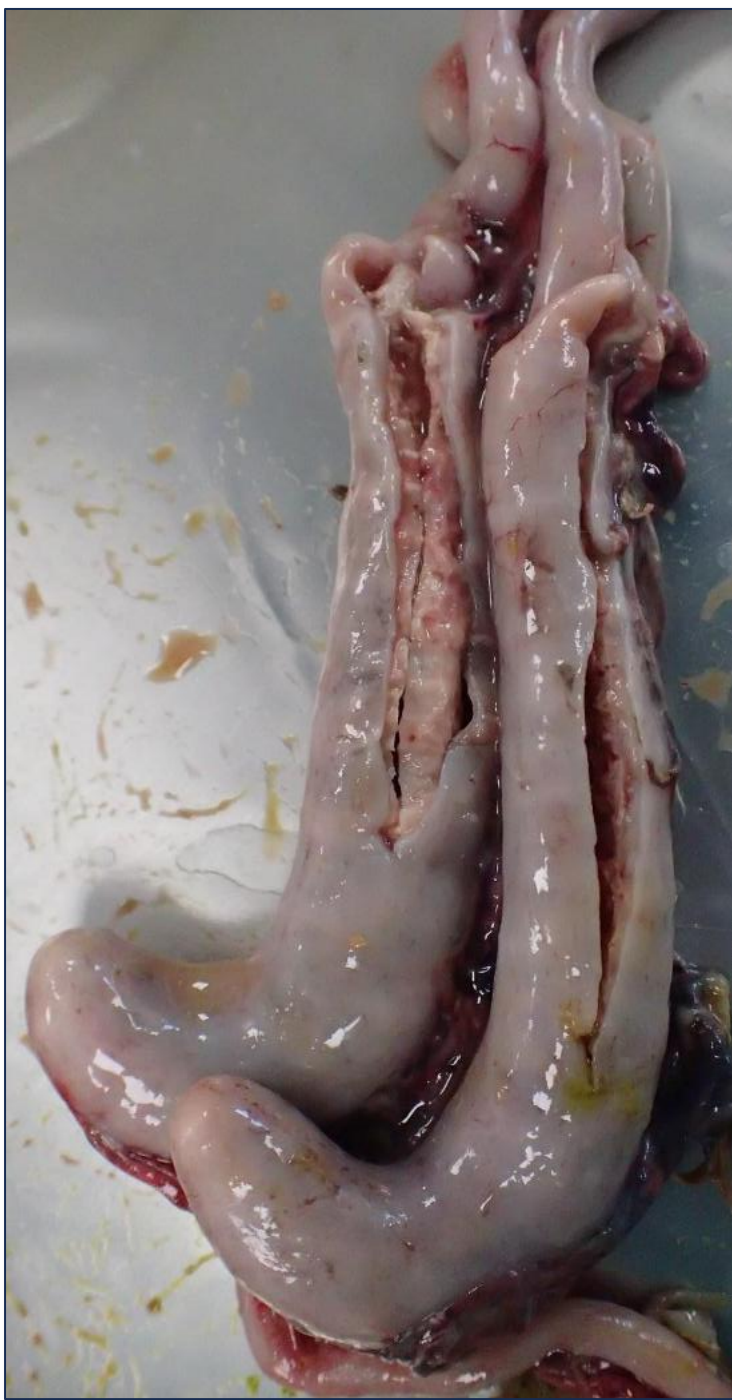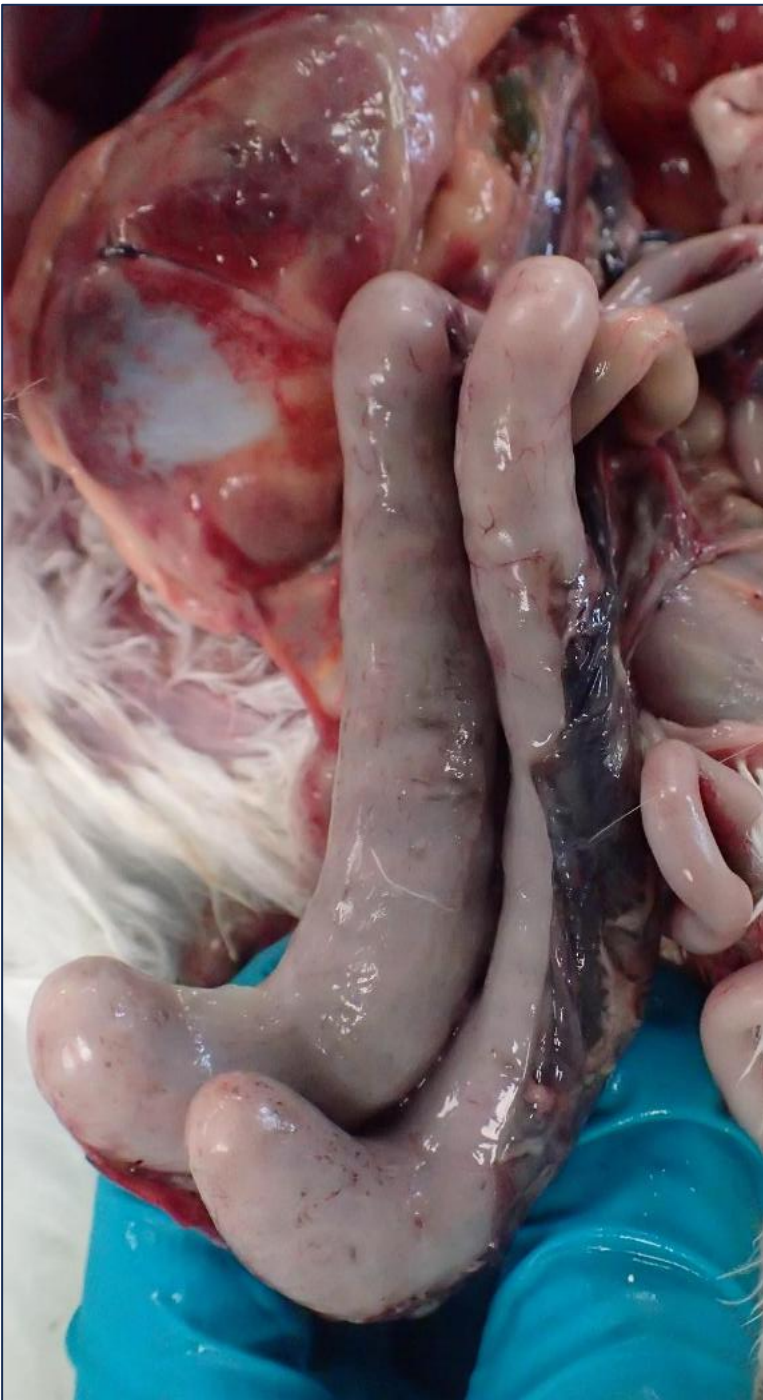


Histomonosis

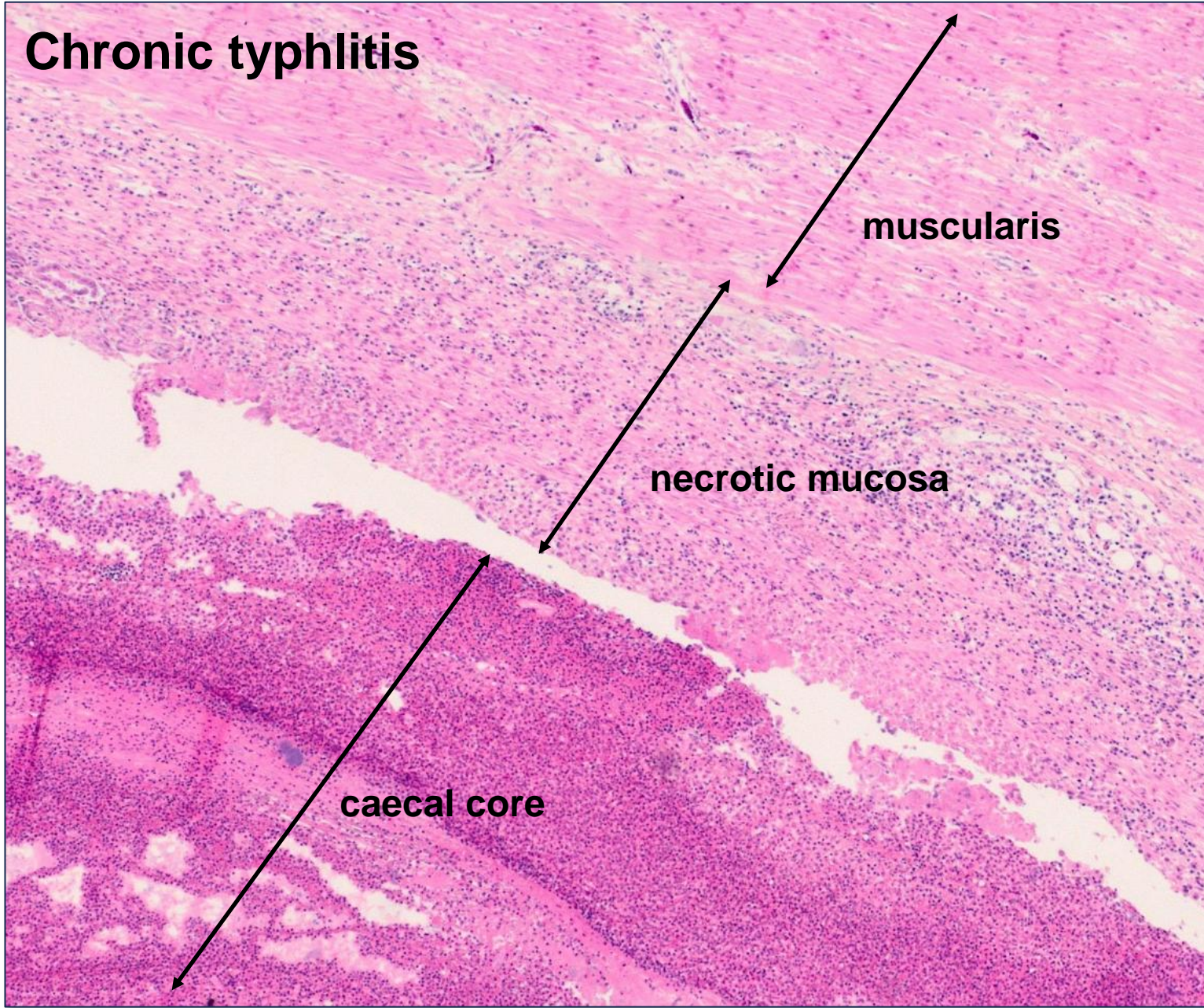
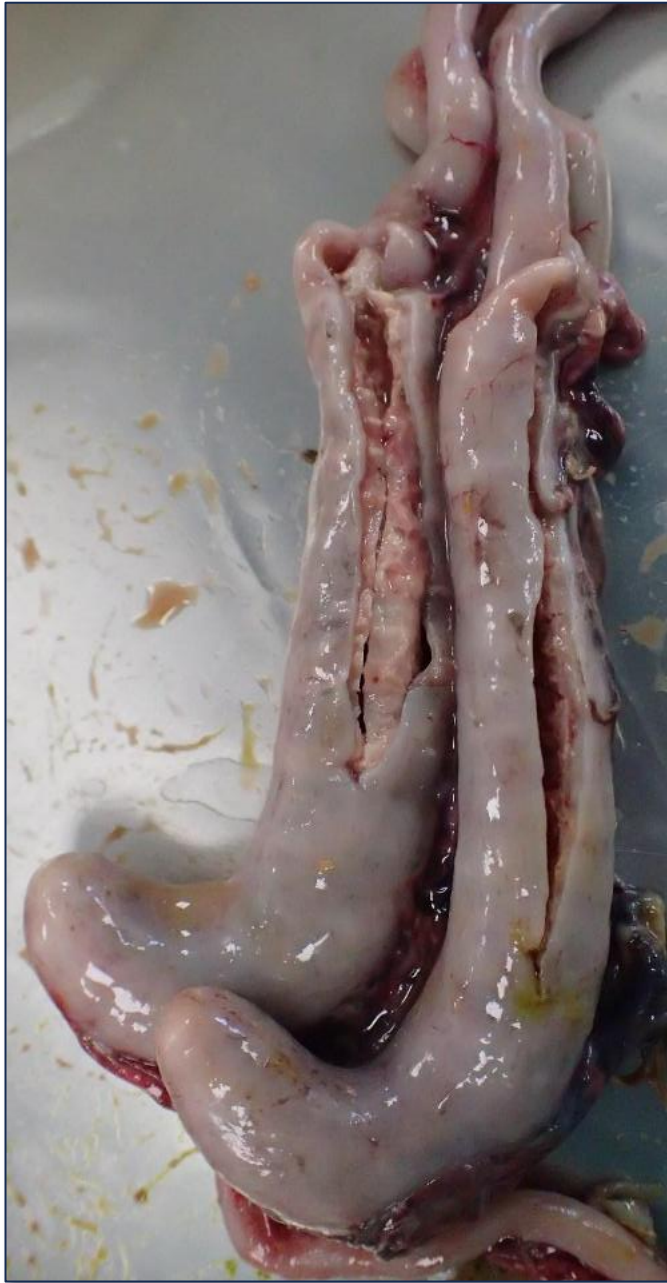



Animal &
Plant Health
Agency



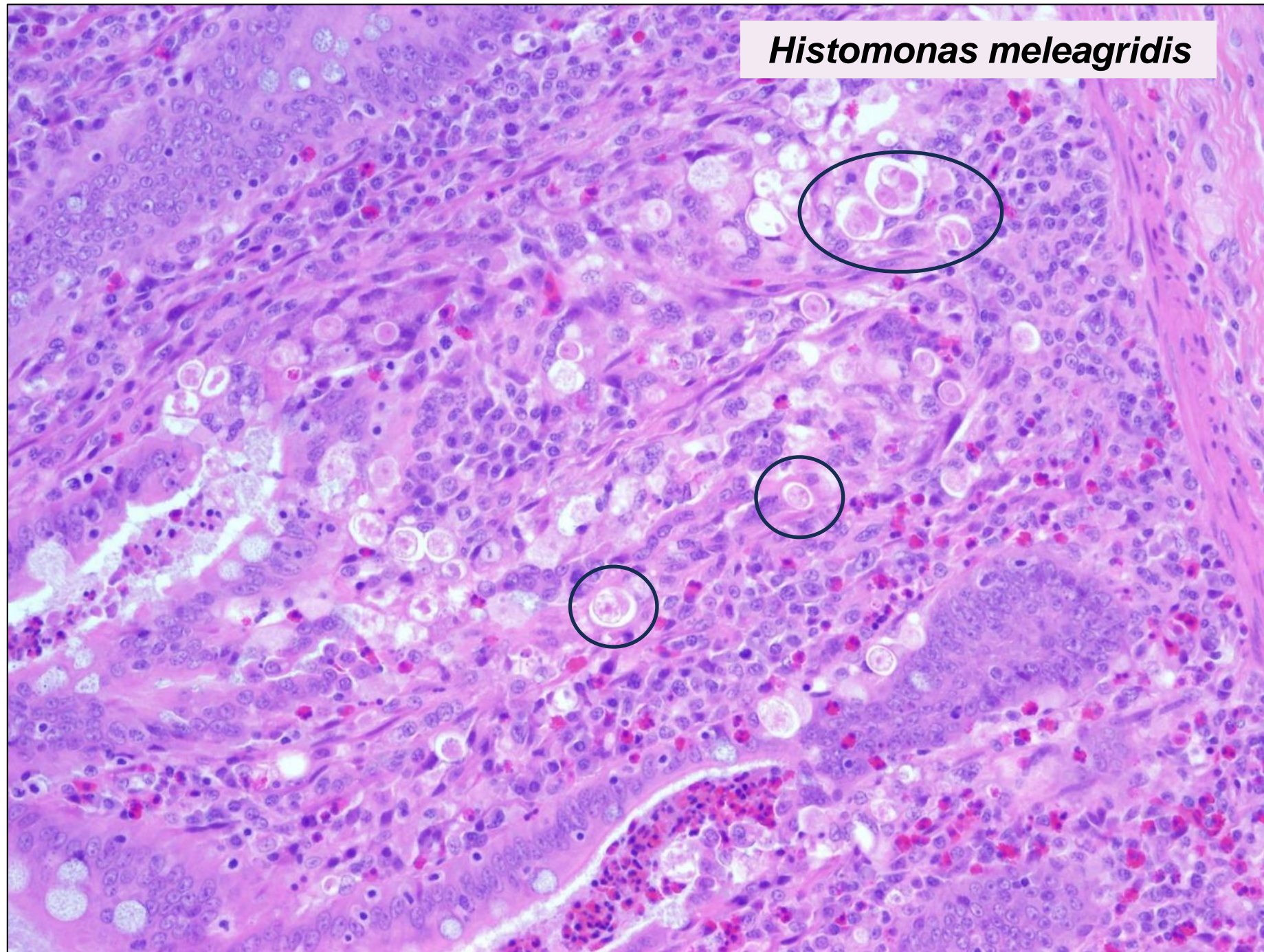
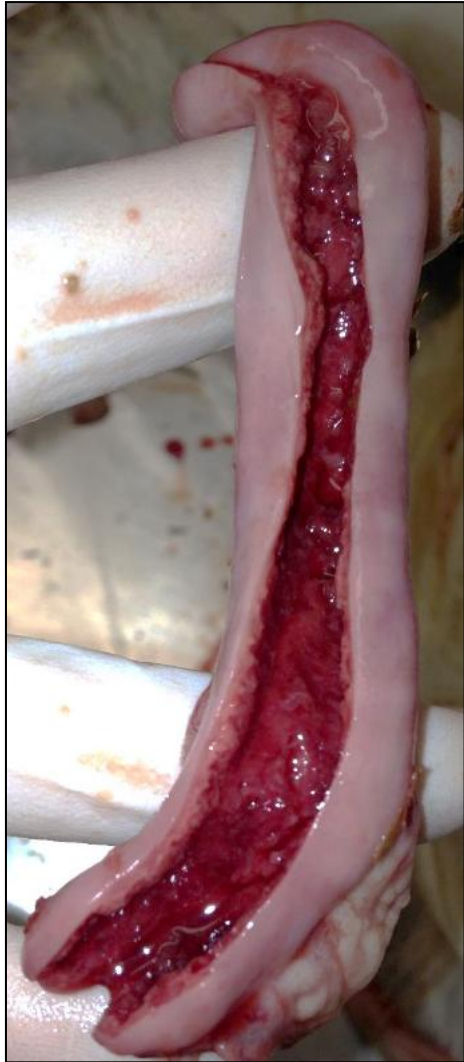
❖ ***Sent to us,
unopened***





Animal &
Plant Health
Agency

Acute typhlitis

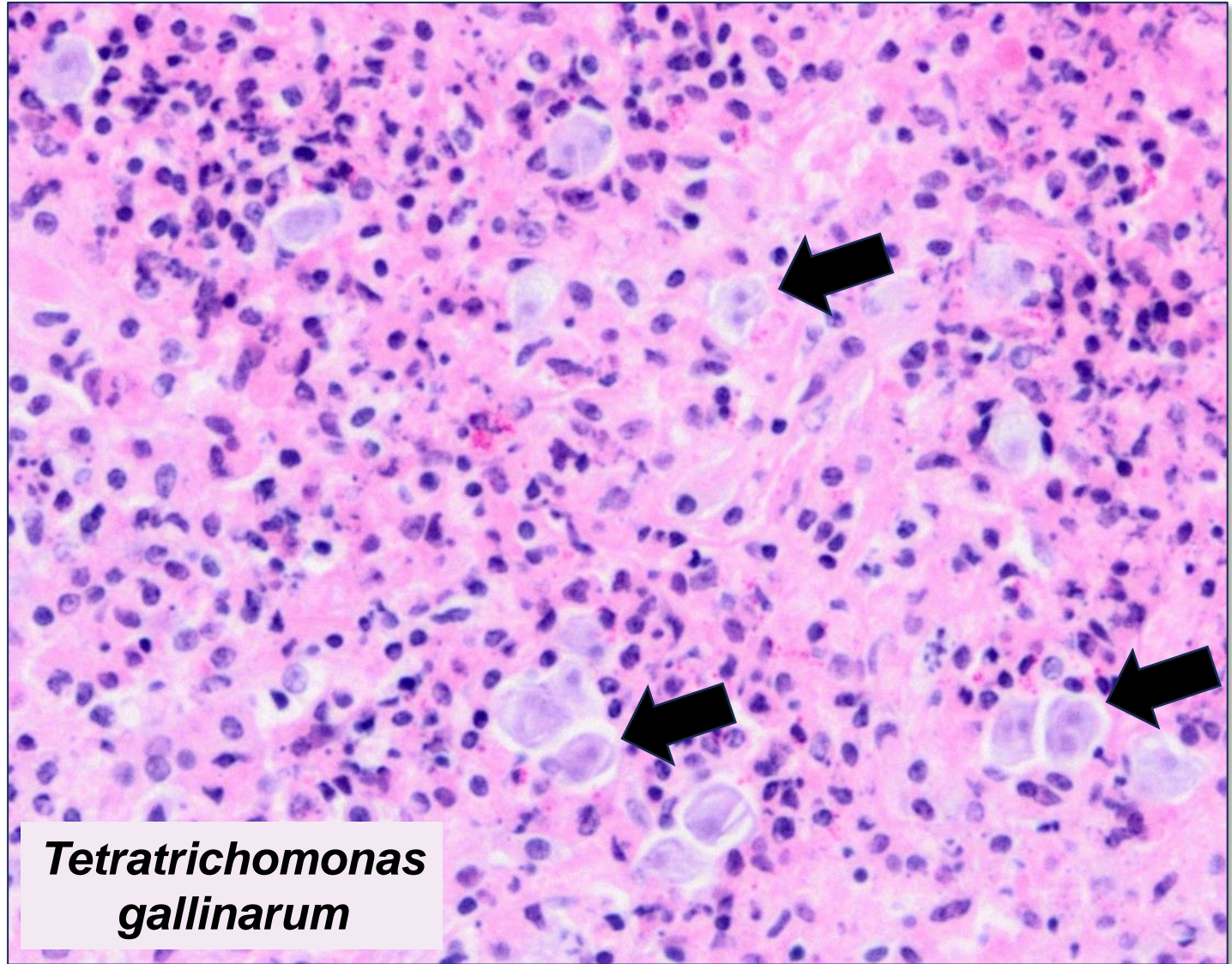
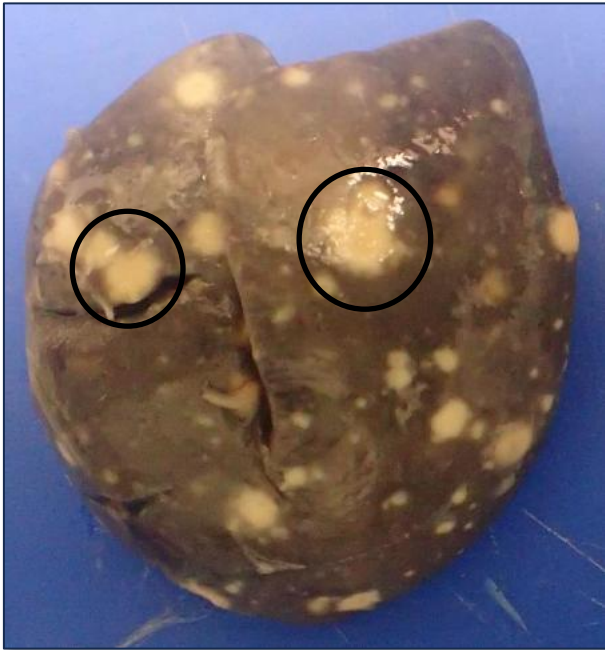




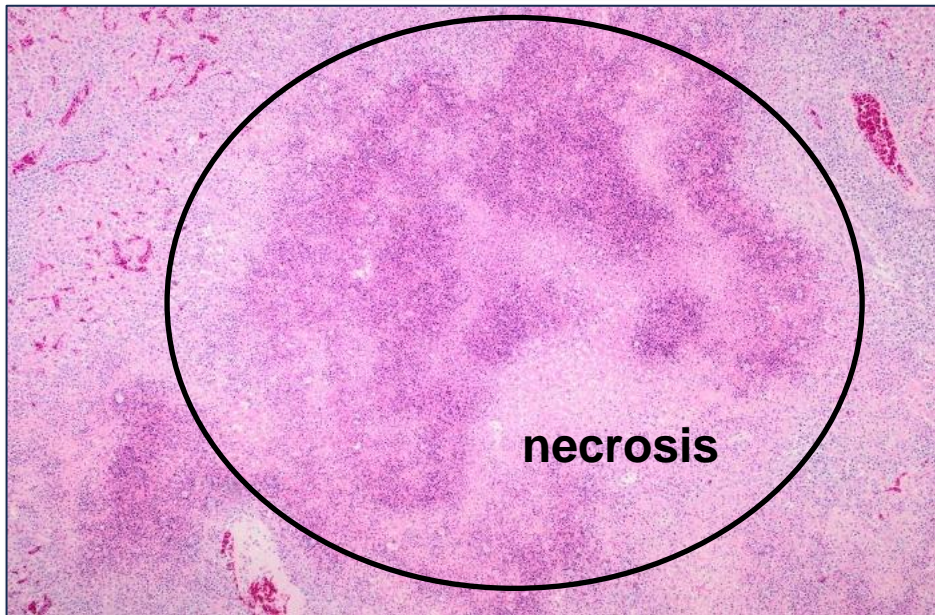
Animal &
Plant Health
Agency

Tetratrichomonosis

Partridge



*Tetratrichomonas
gallinarum*

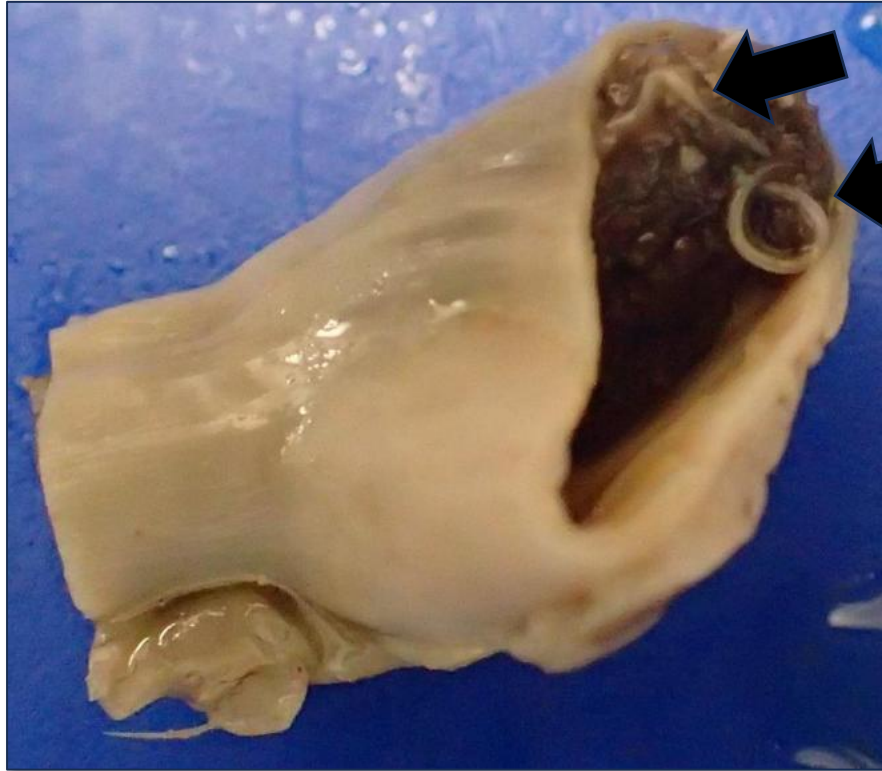


necrosis

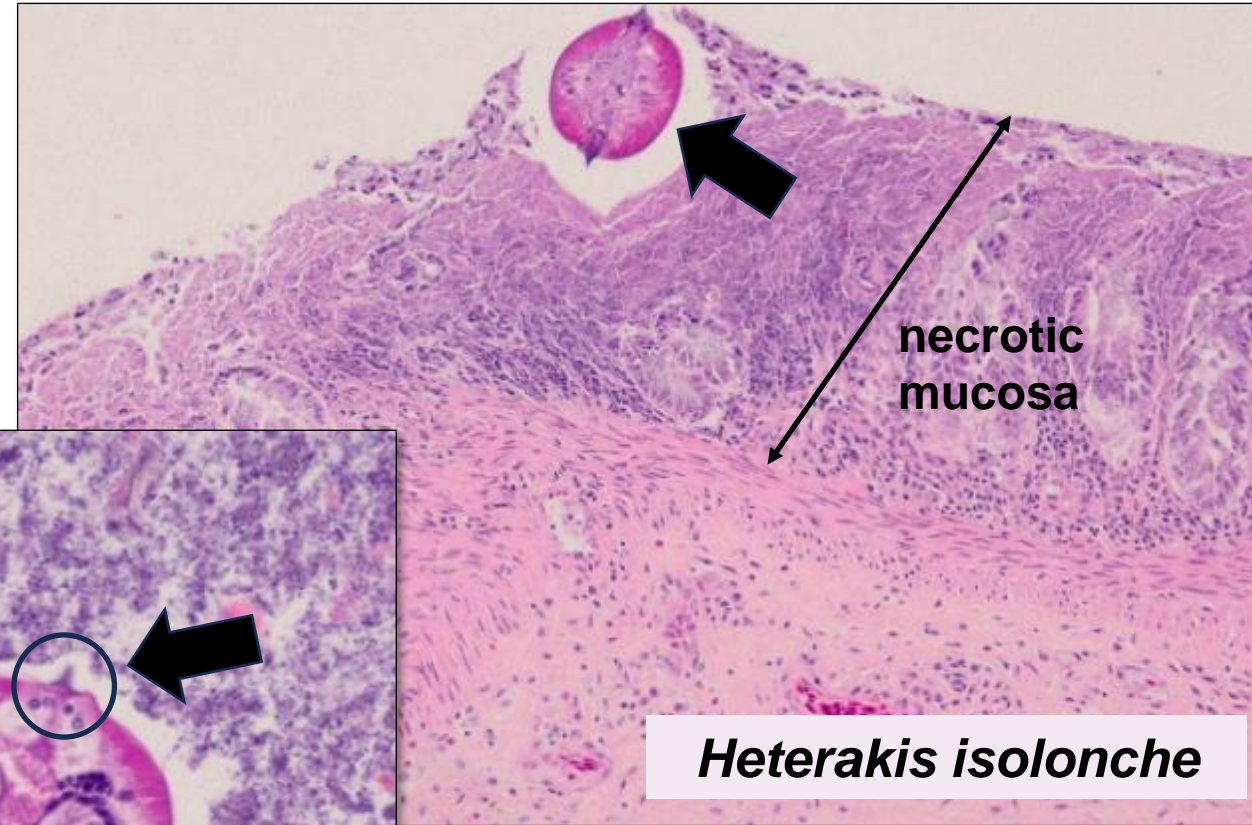
Vet Record Surveillance (September 2024)



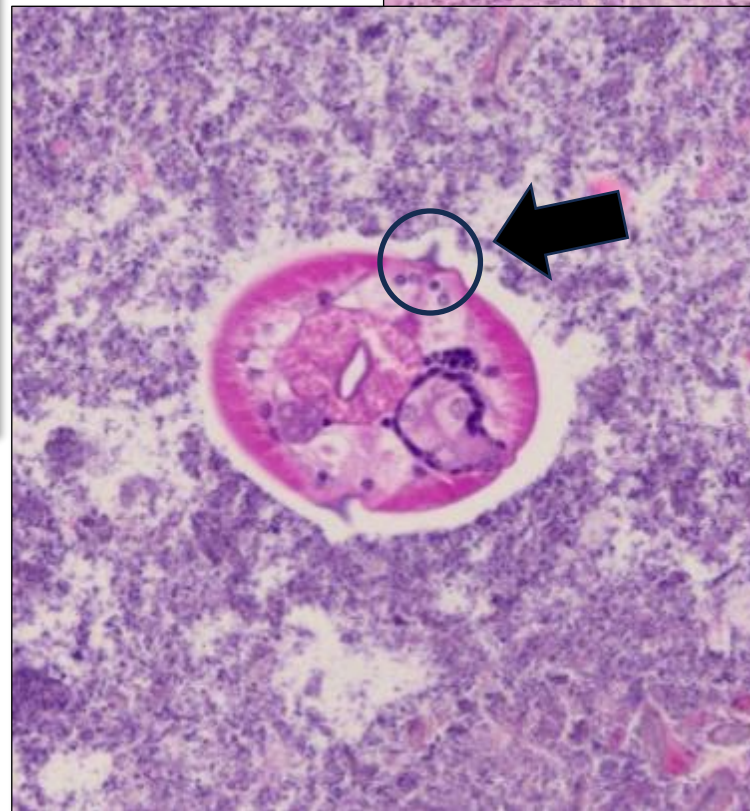
Metazoan parasites: challenging diagnosis



Caecum of a chicken
with nematodes



Lateral alae,
characteristic of
Heterakis spp

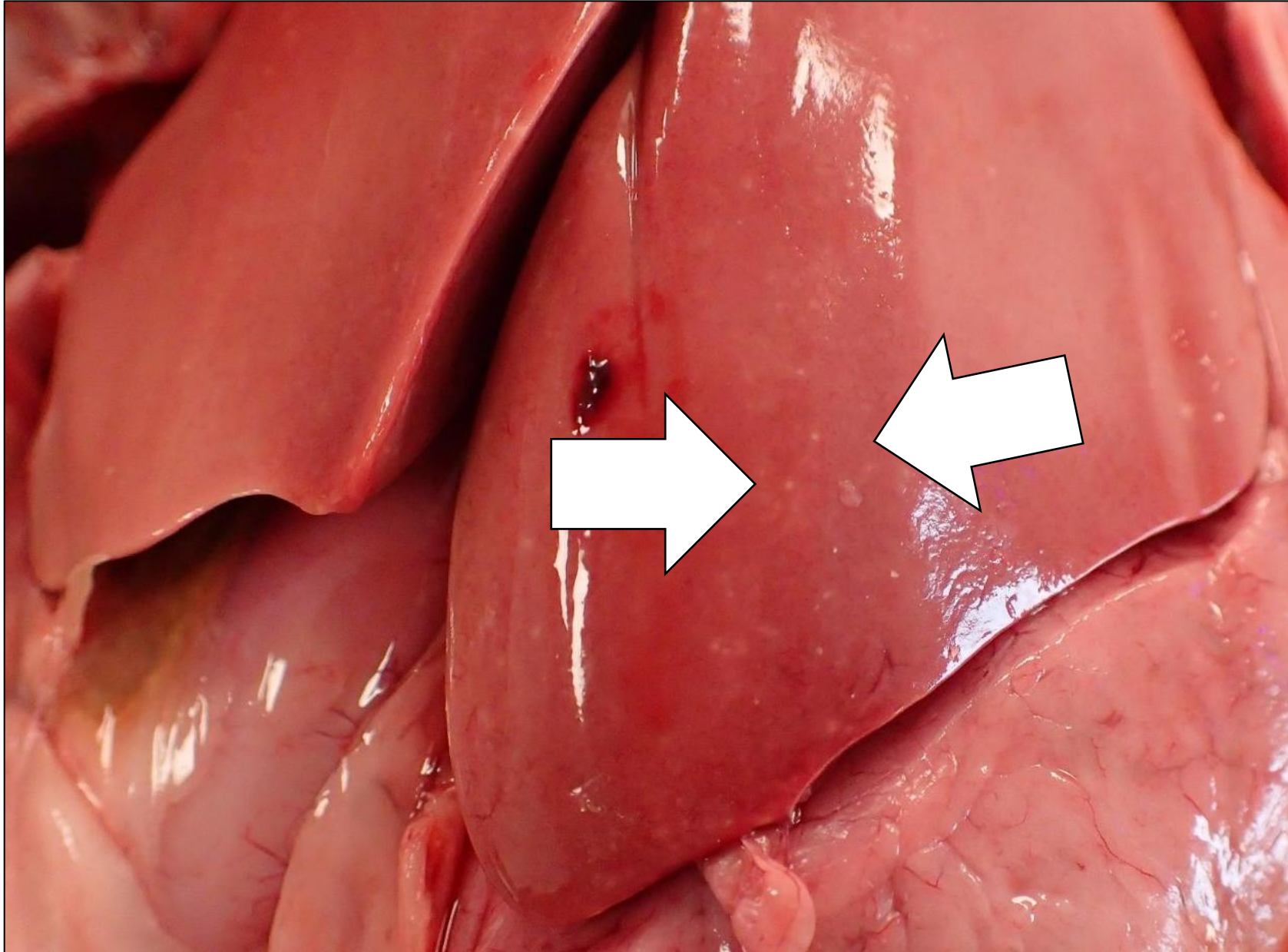




Diagnosis of bacterial diseases

Turkey

***flock with
high mortality***





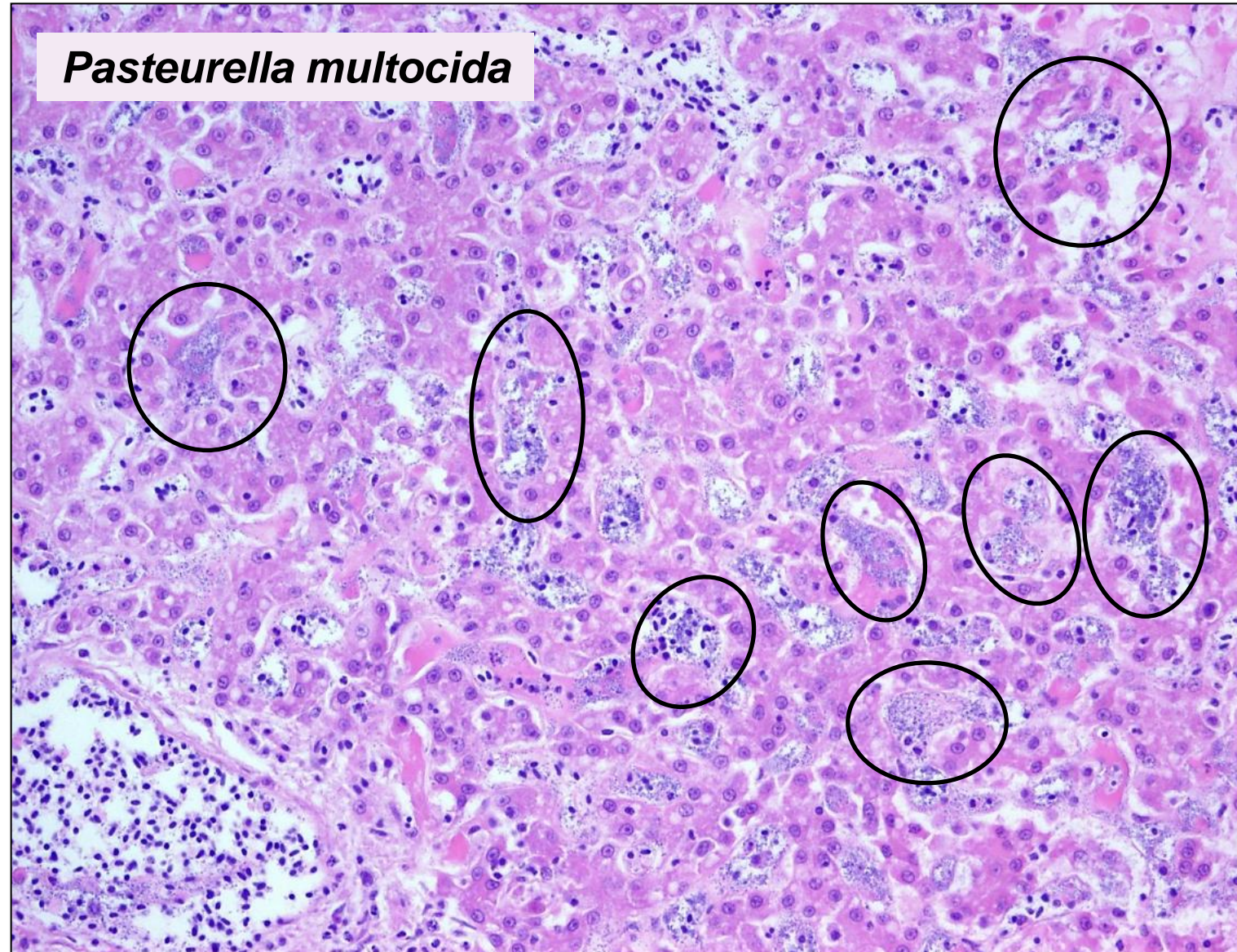
Yes

- ✓ number of bacteria
- ✓ shape
- ✓ mono or polymorphic

No

x species

Gram staining possible
- not always consistent
- not conclusive



Bacteriology needed! Always!



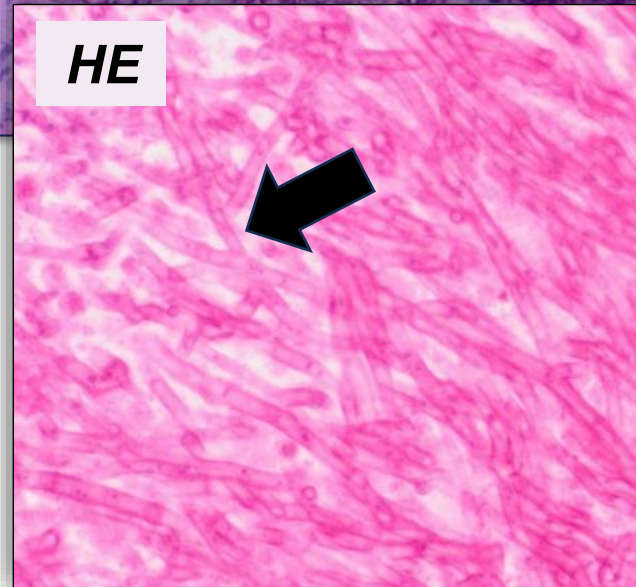
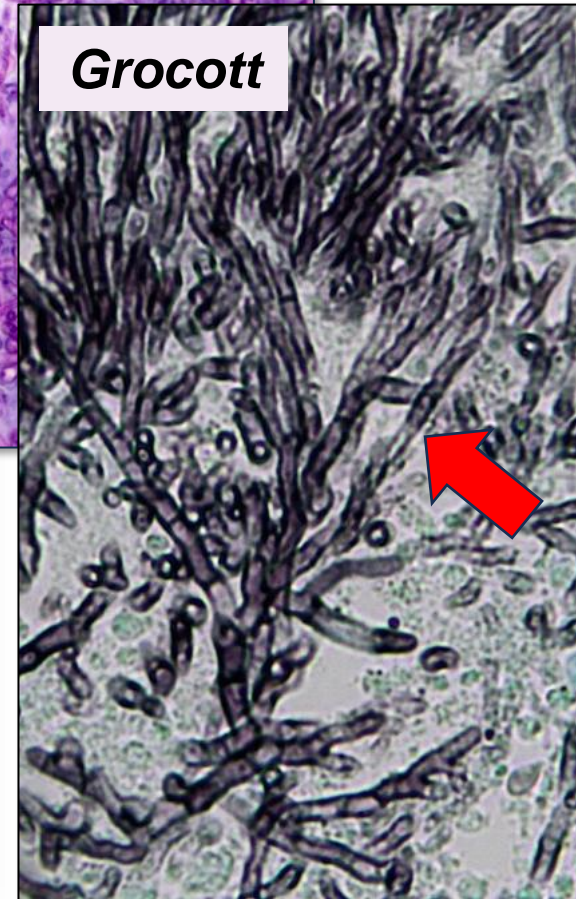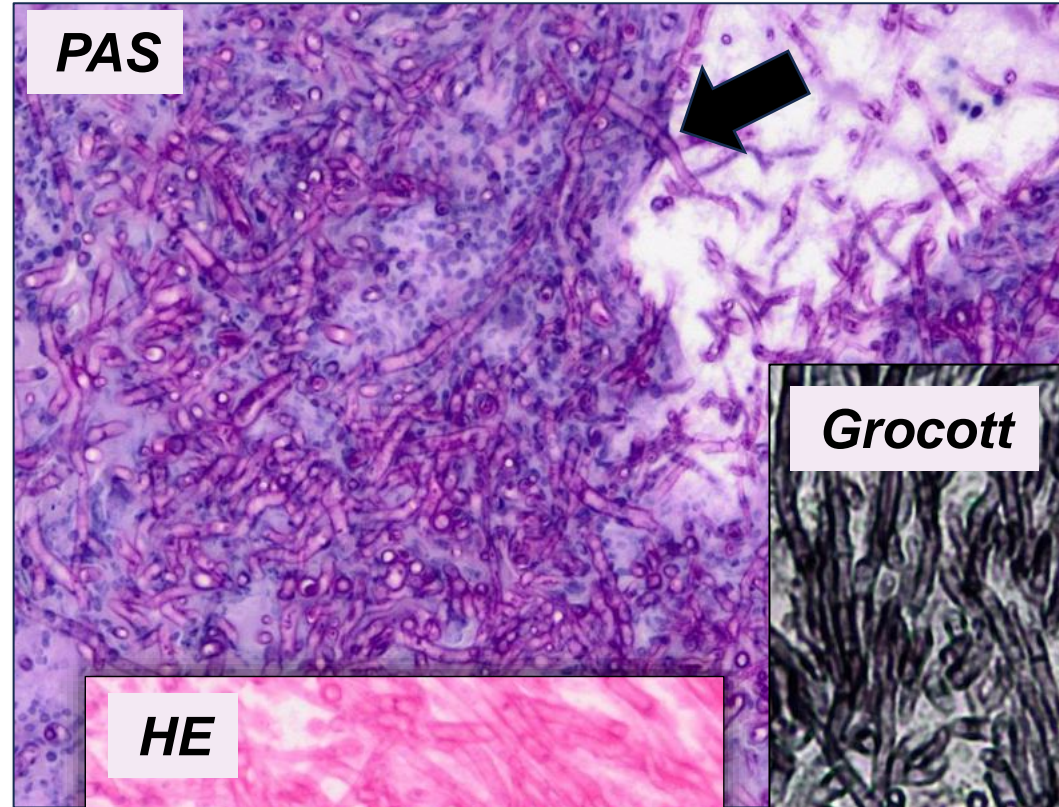
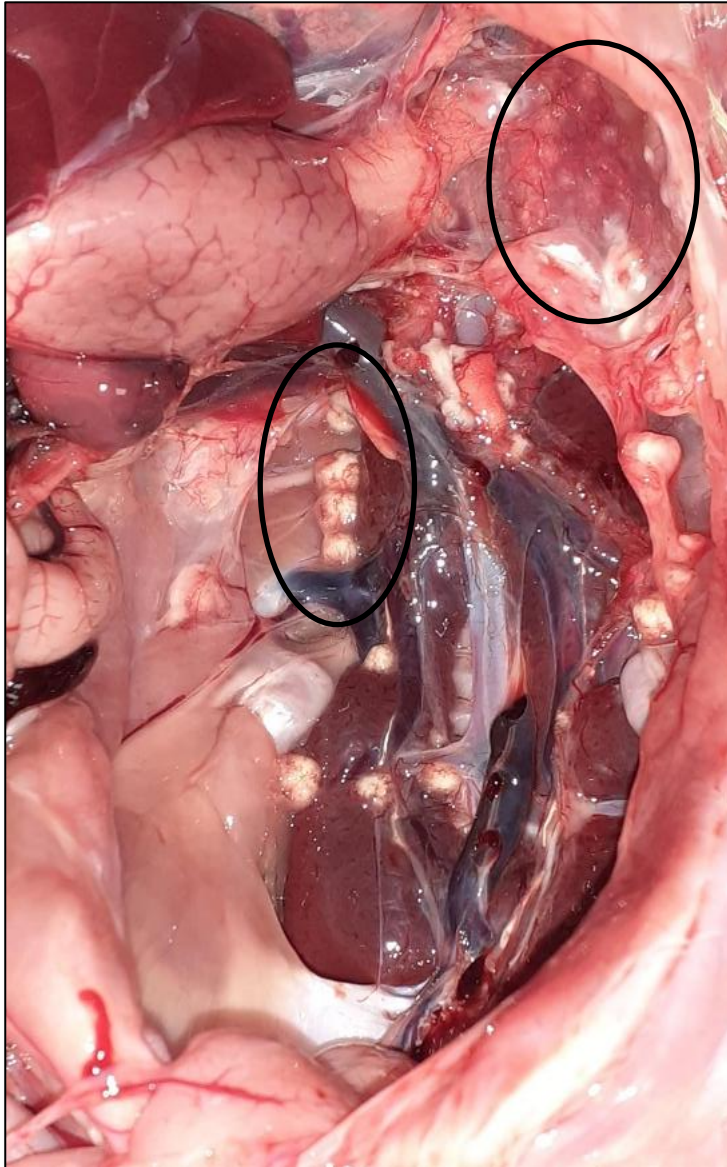
Animal &
Plant Health
Agency

Diagnosis of fungal diseases

Chicken

*flock with
raising
mortality*

*Aspergillus
fumigatus
and
Aspergillus
flavus*



Same as bacteria: cultures needed!!

Concluding comments

APHA histopathology continues to be a valuable tool for the surveillance of poultry diseases in Great Britain.

Histopathology can directly diagnose a wide variety of poultry diseases, generate differential diagnoses, inform further investigative steps.

Expertise within the Avian Expert Group and at APHA Lasswade are always available for consultation.



Thank you!

OGL

© Crown copyright 2024

This information is licensed under the Open Government Licence v3.0.

To view this licence, visit www.nationalarchives.gov.uk/doc/open-government-licence/

Any enquiries regarding this publication should be sent to:

christopher.poulos@apha.gov.uk or catarina.guerreiro@apha.gov.uk

www.gov.uk/apha



@APHAgovuk



@APHAgov



company/aphagovuk



Animal &
Plant Health
Agency